



Tikrit University  
College of Veterinary Medicine

# Auricular Hematoma

Subject name: Practical Surgery

Subject year: five-stage

Lecturer name: Dr. Ali Ghazi Atiyah

Academic Email: [alighazivet@tu.edu.iq](mailto:alighazivet@tu.edu.iq)



SCAN ME

Lecturers link

## **Surgery of Ear**

### **Auricular Hematoma**

- The goals of treating aural hematoma are to remove the blood clot, prevent recurrence, and retain the natural appearance of the ear. It is recommended to treat the hematoma immediately to prevent deformity of the pinna secondary to fibrosis and contracture.
- It has been advocated that the hematoma should not be opened for 5 to 6 days after diagnosis to ensure that coagulation has taken place.
- The simplest technique for drainage of acute hematomas is repeated needle aspiration.

#### **In acute hematoma**

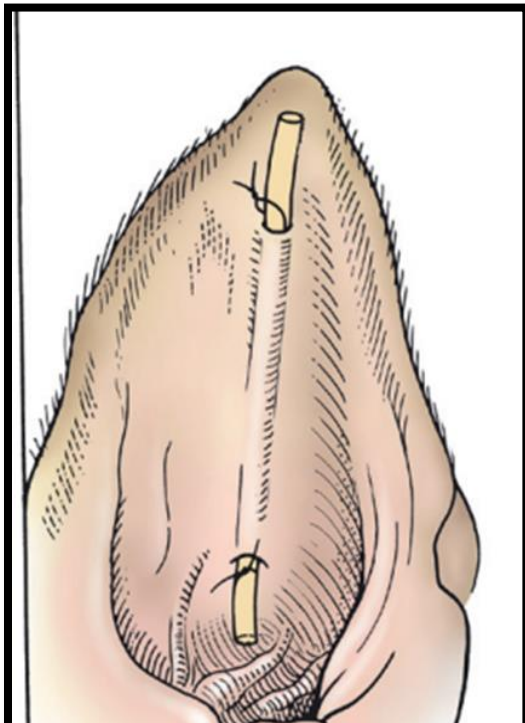
- 1- A Penrose drain can be placed by first making a stab incision in the proximal and distal portion of the hematoma.
- 2- The cavity is emptied and lavaged with sterile saline through the stab holes.
- 3- The Penrose drain is then passed through the cavity, with a portion exiting each stab incision, anchored in place with nonabsorbable sutures, and left in place for 2 weeks to drain passively.

#### **In chronic hematoma**

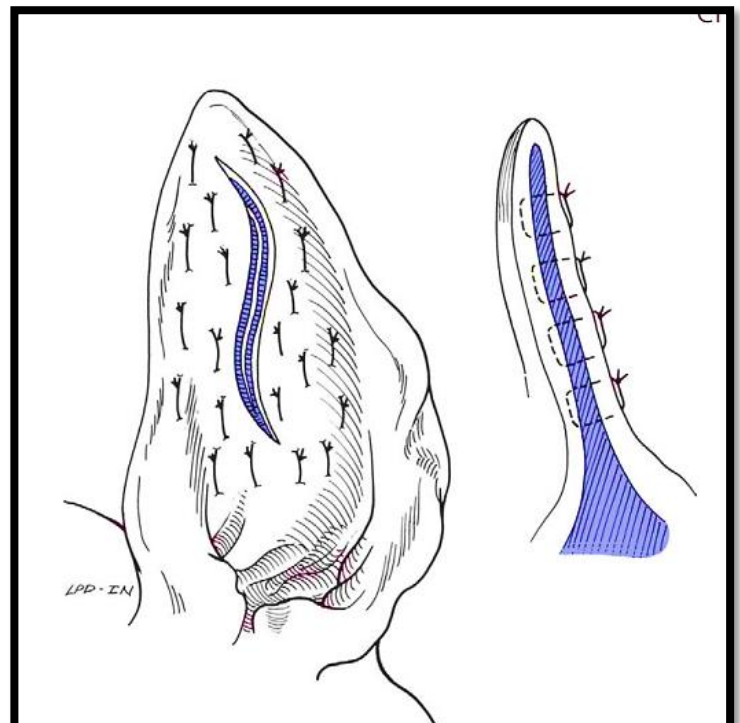
Chronic hematomas are best treated by incisional drainage.

- 1- An S-shaped incision is made on the inner pinna surface through skin and cartilage.
- 2- The clot and fibrin
- 3- are removed, and interrupted mattress sutures of monofilament permanent material are placed full thickness through the pinna and tightened only enough to appose the skin and auricular cartilage.
- 4- Sutures should be placed over the entire surface of the abnormal pinna, with the knots tied on the convex surface.

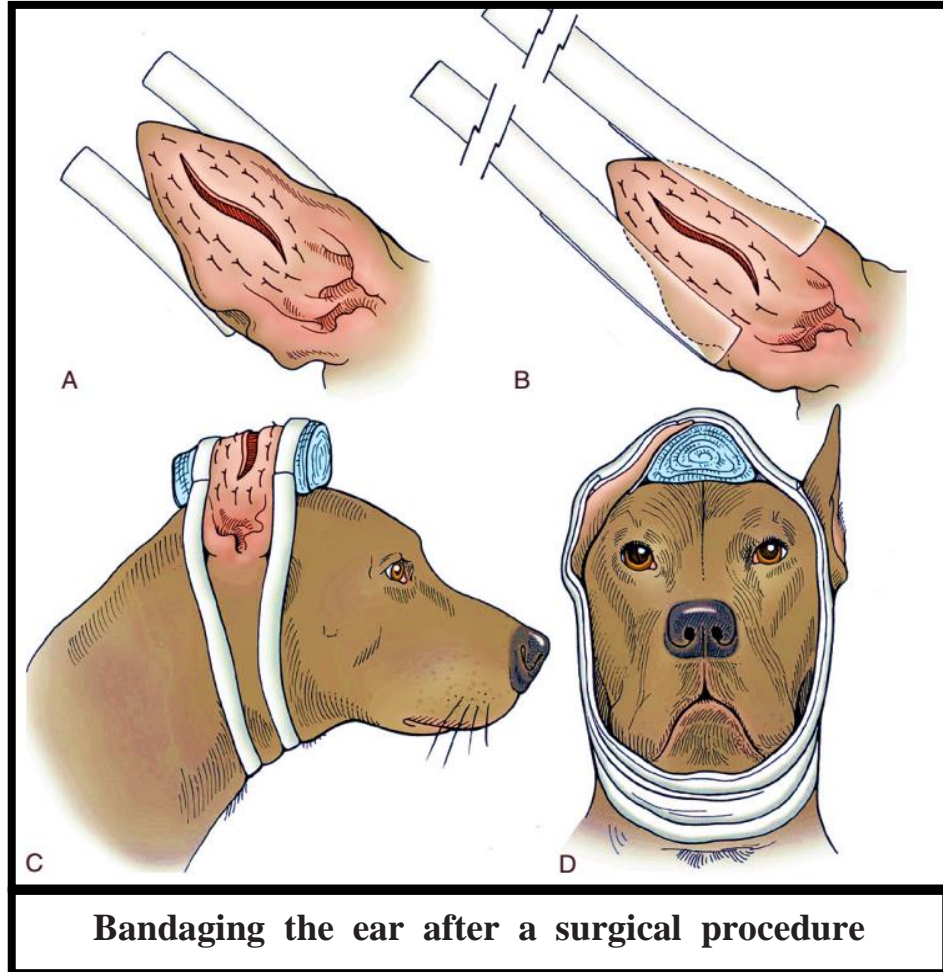
- 5- Sterile gauze can be used as a stent beneath the knots to avoid overtightening the suture.
- 6- In dogs, sutures are placed parallel to the vessels located on the convex pinna surface; it has been recommended in cats, however, to place the sutures haphazardly to prevent systematic interruption of the blood vessels.
- 7- Patients are placed into a protective collar, and sutures are removed after 2 weeks.
- 8- Bandaging the dog's ear is an important part of management of aural hematomas, which This compresses the pinna skin against the auricular cartilage and prevents further trauma to the pinna from scratching or head shaking.
- 9- The ear is bandaged to the top of the head or the neck and left in place until minimal drainage occurs or until the hematoma has resolved and the skin has palpably adhered to the underlying cartilage.



**A Penrose drain tube**



**S-shaped incision**



**Bandaging the ear after a surgical procedure**