



Tikrit University
College of Veterinary Medicine



Nematoda

Subject name: Parasites

Subject year:2024

Lecturer name: Dr.Omaima I.

Lecturer number:7

Academic Email:

dr.omaimapara@tu.edu.iq



SCAN ME

Family : Trichinellidae

Trichinella spiralis

Trichinella spiralis has an extremely broad host range; almost any species of mammal can become infected. Adult worms live around the columnar epithelial cells of the small intestine and the larvae live in striated muscle cells of the same mammal.

Main properties

Trichinella spiralis is the smallest known nematode parasite of humans. The males measure about 1.4 mm to 1.6 mm in length and the females are twice the size of the males. The body of the worm is more slender at the anterior than at the posterior end. In females the uterus is contained in the posterior portion of the worm and is filled with the developing eggs. The anterior end of the female contains hatching juveniles.

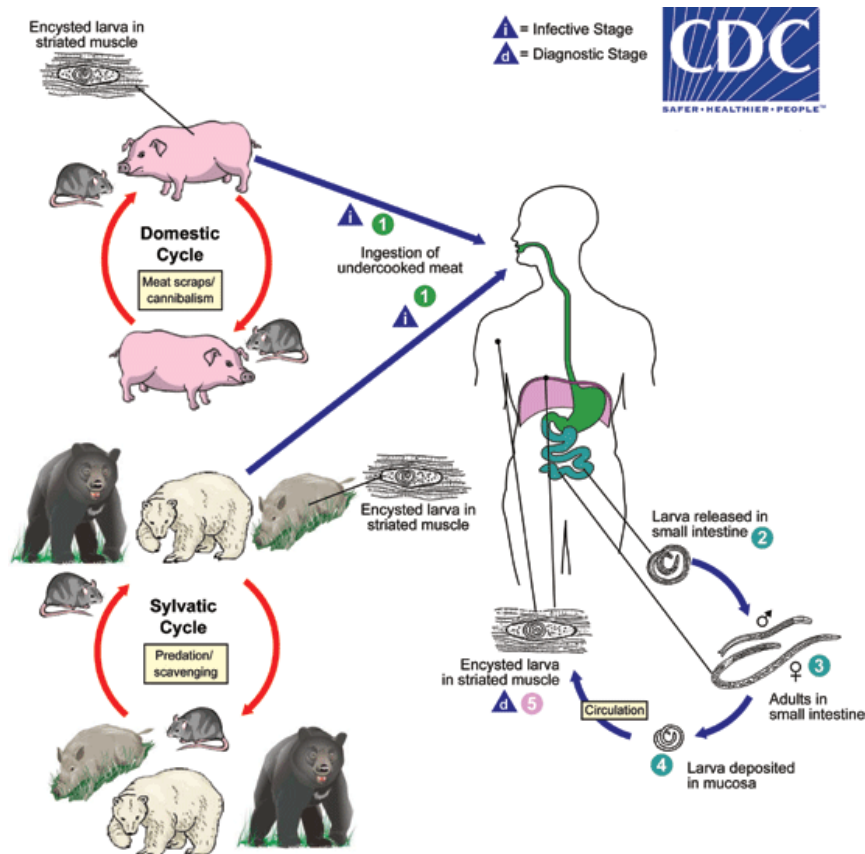
Life cycle

*Infection occurs by ingesting encysted **larvae** in undercooked meat.

*The larvae excyst and develop to **adults** in the small intestine.

*Adults attach to the intestinal mucosa and begin to release **larvae** in one week. The adults live for about 4 weeks and may release more than 1000 larvae.

* **Larvae** penetrate the intestinal wall and move to muscle tissue where they encyst in individual cells (nurse cells). Active muscles, such as the diaphragm and tongue, often have the greatest numbers of larvae.



Clinical signs

Infection with *Trichinella spiralis* may be asymptomatic, especially in light infections. Adults in the intestine may cause diarrhea, abdominal pain, and vomiting. Larvae moving into the tissues may cause facial swelling, fever, muscle pain, splinter hemorrhages (under fingernails) or rashes.

Heavy infections may lead to heart problems or central nervous system involvement. Large numbers of larvae in other muscles may lead to soreness and weakness which often lessens over time.

Diagnosis

Muscle biopsy is used for trichinosis detection. Several immunodiagnostic tests are also available. In pigs, ELISA testing is possible as a method of diagnosis.

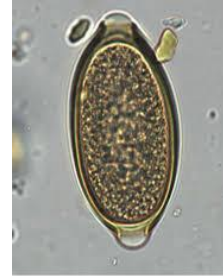Trichuridae

Trichuris ovis

The adult whipworm (*Trichuris ovis*) lives in the cecum and colon of goats, sheep and cattle. The worm buries its long, thin neck into the tissue feeding on blood from vessels. The egg has a plug on both ends making it one of the easier eggs to identify on a fecal.

Main properties

This species of whipworm is white and is known to have a long, thin neck that composes two-thirds of its body, and a short, thick posterior. The male organisms of *T. ovis* usually range from 53.04mm-75.08mm in length, while their female counterparts are approximately 32.03-70.19mm in length. The spicule length is 4.18-5.62mm for both genders. Both genders also have bacillary bands.



Trichuris

Life cycle

Trichuris ovis life cycle

Direct: unembryonated, bipolar eggs pass out in the feces, requiring 3 or more weeks to develop to **infective L1s** in the egg. The infective eggs are ingested by the definitive host. Eggs hatch in the small intestine, **larvae migrate in the large intestinal mucosa**, and then mature to adults in approximately 60 days.

July 12, 2014 46

Pathogenicity and clinical signs

Like all whipworms, *T. ovis* primarily inhabit the host's cecum. However, sheep and goats are rather resistant to the parasite infection and often do not experience many symptoms. If the host is heavily infected, a large portion of the blood vessels located in the cecal wall will be consumed. This eventually results in the thickening of the wall, thus

preventing that region of the large intestine from absorbing fluids causing the host to have diarrhea.

Diagnosis

Lemon-shaped eggs in faeces of infected sheep. Worms found at post mortem.

Treatment

Typically, cases are treated with either mebendazole or albendazole, but efficacy of such products are uncertain.