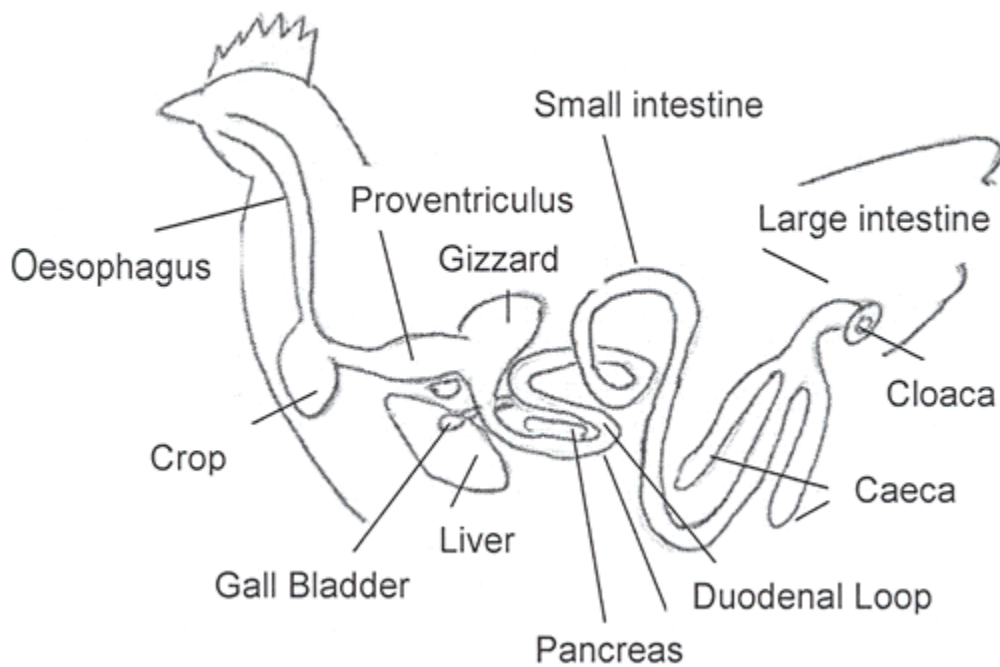
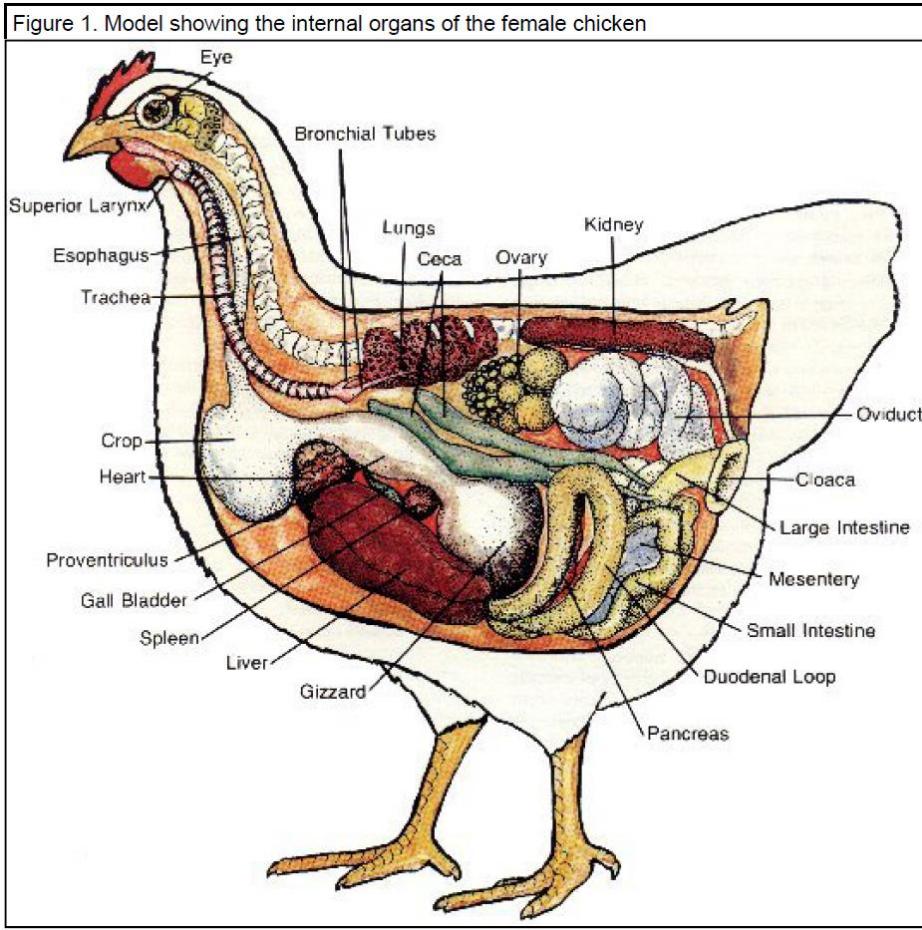


Practical anatomy



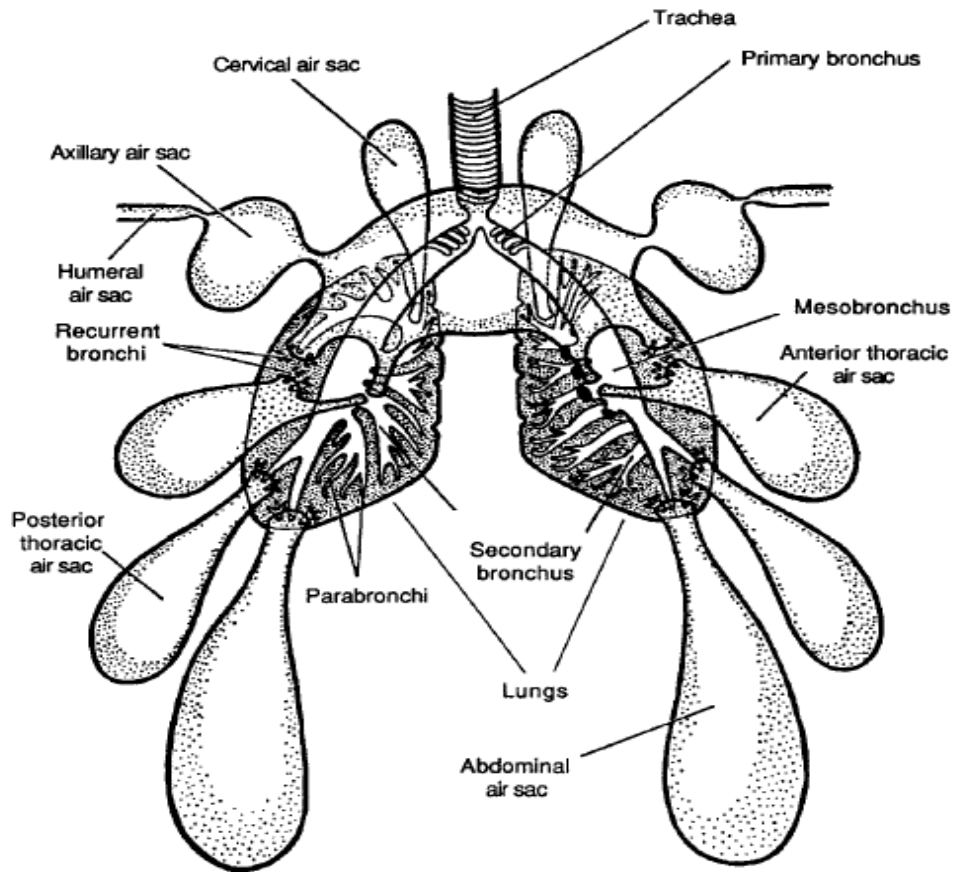
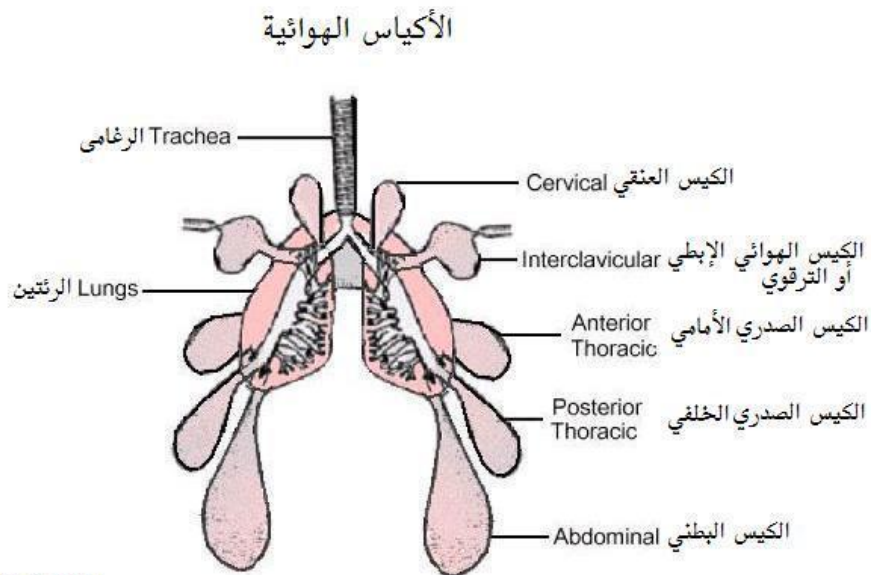
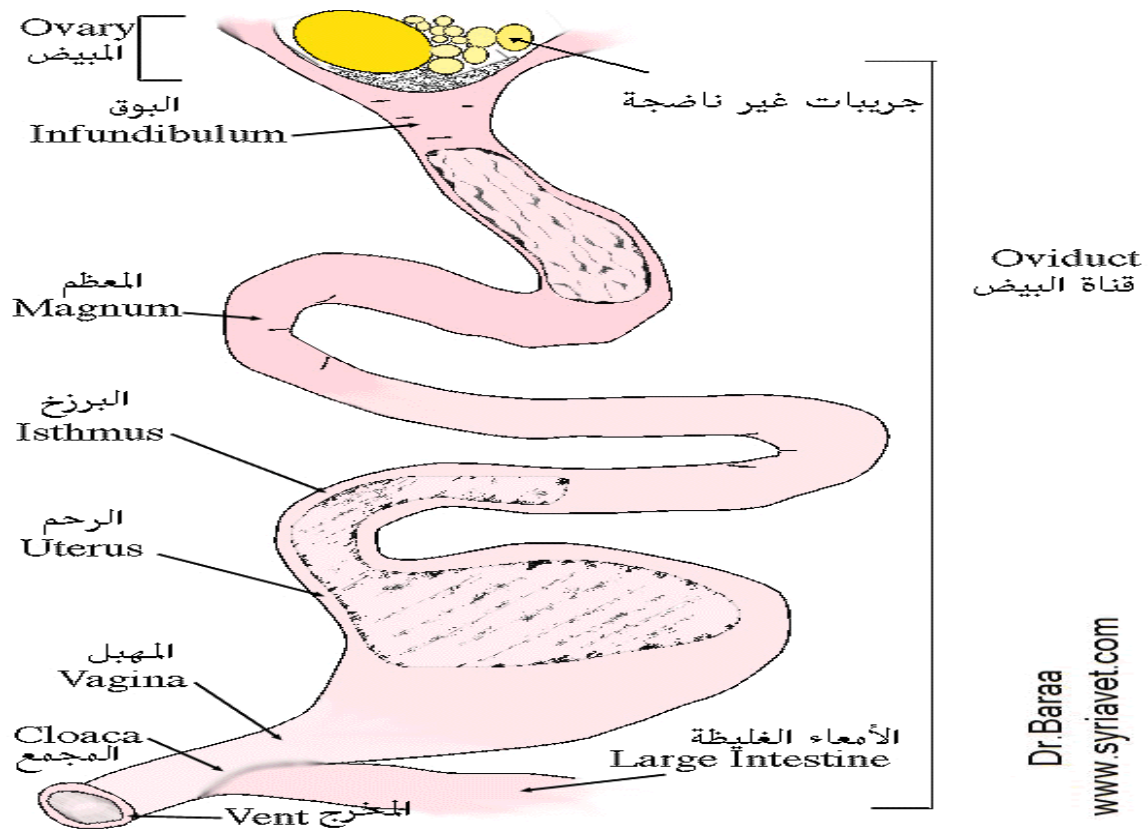


Fig. 2.8. Respiratory system, showing the relationship between the lungs, the parabronchi and the air sacs, which occupy both the peritoneal cavity and some of the bones (after Ede, 1964).





Cloaca

المجمع

