



Tikrit University
College of Veterinary Medicine

Lecture Title

Font (28)

Font type (pt bold heading)

Subject name: The eye

Subject year: 2025

Lecturer name: Bader khatlan hameed

AcademicEmail: Baderkatlan74@tu.edu.iq

iq

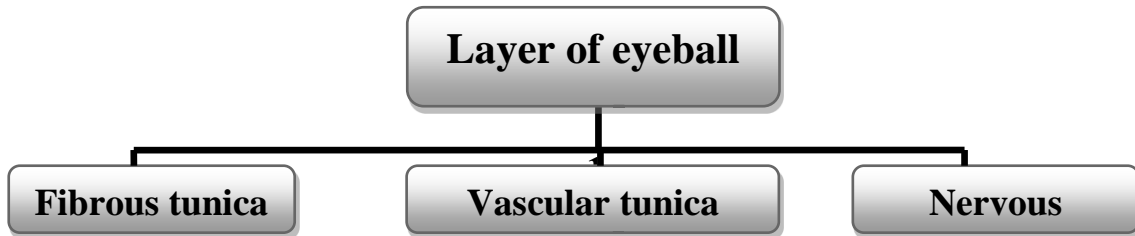
Font (20)



SCAN ME

Lecturers link

The eye



1-Fibrous tunica consist of :

- a. Cornea.
- b. Sclera.

2-Vascular layer consist of :

- a. Choroid.
- b. Ciliary body
 - Ciliary muscle
 - Ciliary processes
- c. Iris .

- Tapetum lucidum

3- Nervous layer consist of :

- a- Retina
 - Zona iridica
 - Zona ciliaridica
 - Zona optica

- Optic disc
- Chambers:
 - 1- Anterior chamber
 - 2- Posterior chamber
 - 3- Vitreous chamber
- **Aqueous humor**
- **Vitreous humor**


- **The Accessory structure :**

- 1-Upper & lower eye lid
- 2- Lateral & medial commissures or canthi
- 3-Eye lashes
- 4-Lacrimal gland
- 5-Conjunctiva
- 6-Third eye lid (nictitating membrane)

- **The Muscle of the eye :**

- 1-Levator palpebral superior properious muscle
- 2-Dorsal rectus muscle
- 3-Ventral rectus muscle
- 4-Medial rectus muscle
- 5-Lateral rectus muscle
- 6-Dorsal oblique muscle
- 7-Ventral oblique muscle
- 8-Retractor bulbils muscle

- **The Nerve supply :**

- 1- Oculomotor  Dorsal branch (1,2)
Ventral branch (3,4,7)
- 2-Trochlear (6)
- 3-Abducent (5,8)

