

Testes and Scrotum

Testes and Epididymides

The testes, or male gonads, are oval in shape and directed dorsocaudally. Each testis with its epididymis and distal spermatic cord is located within the scrotum. The left testis is farther caudal than the right testis; this orientation decreases pressure on each testis and allows the testes to glide easily on each other

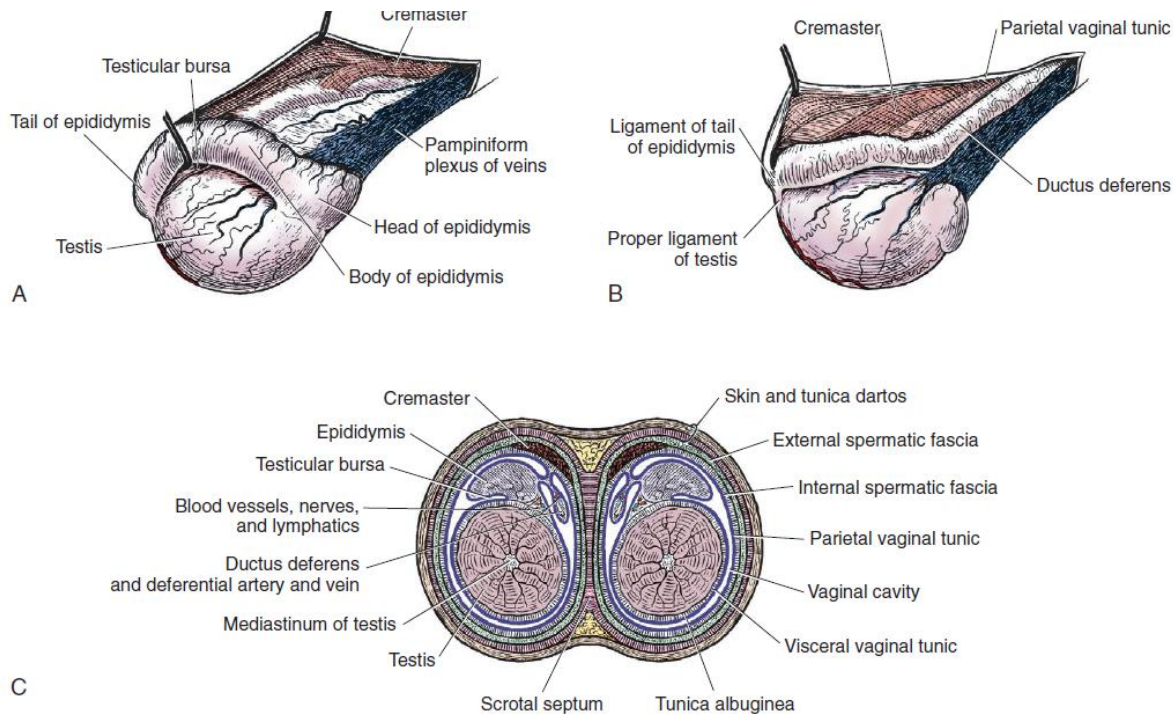
The epididymis is tube that connects the efferent ducts from the testicle to the vas deferens. The epididymal tail is attached to the testis by the proper ligament of the testis. The ligament of the tail of the epididymis attaches the testis and epididymis to the vaginal tunic and spermatic fascia.

The tail of the epididymis continues up into the spermatic cord as the ductus deferens (vas deferens).

The ductus deferens enters the abdominal cavity through the inguinal canal, crosses ventral to the ureter at the lateral ligament of the bladder, and penetrates the dorsal prostate to insert into the prostatic urethra

The spermatic cord contains the ductus deferens and its associated artery and vein, testicular artery, pampiniform plexus, lymphatic vessels, and nerves. The cremaster muscle is formed from the internal abdominal oblique and the transversus abdominus.

The cremaster muscle raises and lowers the testicles, depending on temperature, so that testicular temperature remains slightly below body temperature to enhance spermatogenesis



DISORDERS

Testes

Anorchism is the absence of both testicles;

monorchism is the absence of one testicle.

Cryptorchidism

Cryptorchidism is a condition in which one or both testicles do not descend into the scrotum. The testis originates on the caudal ridge of the kidney in the abdominal cavity of the fetus, passes through the inguinal canal, and descends into the scrotal cavity.

Cryptorchidism is described by location (abdominal, inguinal, prescrotal), side (right, left), and number of testicles affected (unilateral, bilateral).

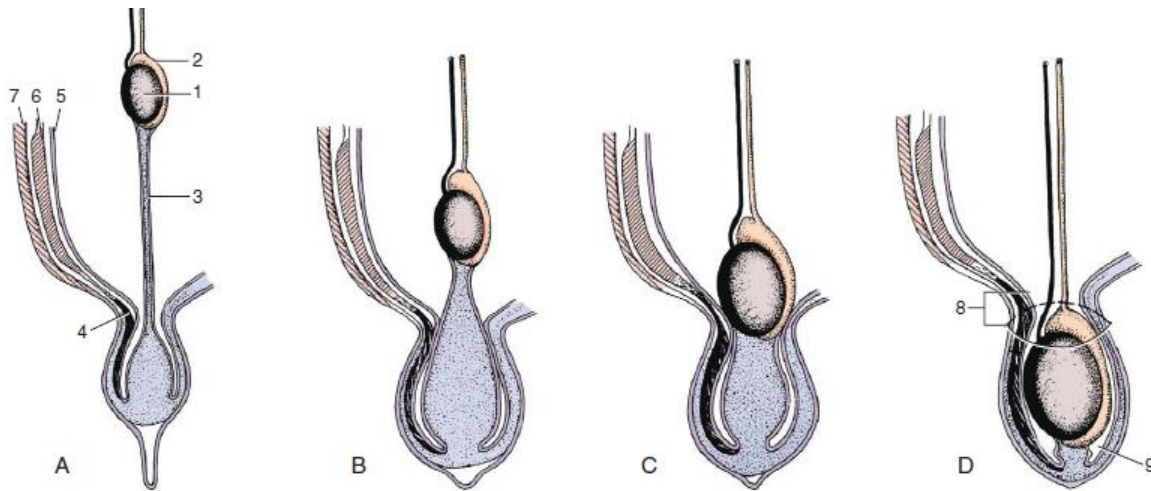


Figure 111-4 Schematic drawing of the descent of the testis in the dog. (1) Testis; (2) epididymis; (3) gubernaculum; (4) cremaster muscle; (5) peritoneum; (6) internal abdominal oblique; (7) external abdominal oblique; (8) inguinal canal; and (9) vaginal cavity. (From Baumans U, Dijkstra G, Wensing CJG: Testicular descent in the dog. *Zbl Vet Med DC Anat Histol Embryol* 10:97-110, 1981.)

Orchitis and Epididymitis

The incidence of epididymitis and orchitis in dogs is unknown but is considered to be relatively uncommon. Primary causes of orchitis and epididymitis include infectious causes such as bacterial (*Brucella canis*, *Klebsiella* spp.), viral (canine distemper), fungal (*Rhodotorula glutinis*), or rickettsial (Rocky Mountain spotted fever) infection.

Secondary causes include trauma to the testicle or epididymis, which can result in secondary inflammation or infection, and ascending infection from the prostate or urinary tract.

Testicular Torsion

Testicular torsion is a rare condition in small animals. Torsion of a testicle is more often associated with an intra-abdominal testicle. Testicular torsion can be seen with testicular Neoplasia.

Testicular torsion is an emergency situation; without prompt diagnosis and surgery, death can ensue.

Diagnostics include abdominal radiography, abdominal ultrasonography, and abdominal exploratory surgery. A palpable intra-abdominal mass may also be found during physical examination.

On ultrasound evaluation, the testicle may appear enlarged and globoid.

Testicular Neoplasia

Common testicular neoplasms include interstitial cell (Leydig) tumors, Sertoli (sustentacular) cell tumors, and seminomas.

Epididymal Occlusion

Occlusion of the epididymis can result from aplasia, acquired duct occlusion, and abnormal position of the epididymis in relation to the testes. Obstruction of the flow of spermatozoa can result in formation of spermiostatic granulomas or cysts.

Scrotum

Primary conditions resulting in scrotal surface lesions include trauma, ulcerative dermatitis, sunburn, frostbite, bite wounds, scratches, self-mutilation, contact irritants, and neoplasia.

SURGICAL TECHNIQUES

Canine orchietomy (castration) can be performed with an open or closed technique. With a closed technique, the parietal vaginal tunic is left intact. With an open technique, the parietal vaginal tunic is incised.

Closed Technique

During closed castration, use a **three-clamp technique**, with application of a circumferential ligature proximal (closest to the patient's body).

This circumferential ligature will prevent bleeding in the event that subsequent transfixing ligatures penetrate blood vessels.

The most proximal clamp (closest to the patient's body) is then removed, and a second circumferential or transfixation ligature is placed in its crushed area, distal to the first ligature.

When placing a transfixation ligature, the needle is inserted through an avascular area of the spermatic fascia.

After passing the needle through the fascia, the two simple throws are tied on the testicular blood vessel side first.

The suture end is passed around the cord, and the encircling ligature is tied.

The spermatic cord is then transected between the remaining clamps. The remaining testis is removed in the same manner through the same prescrotal skin incision.

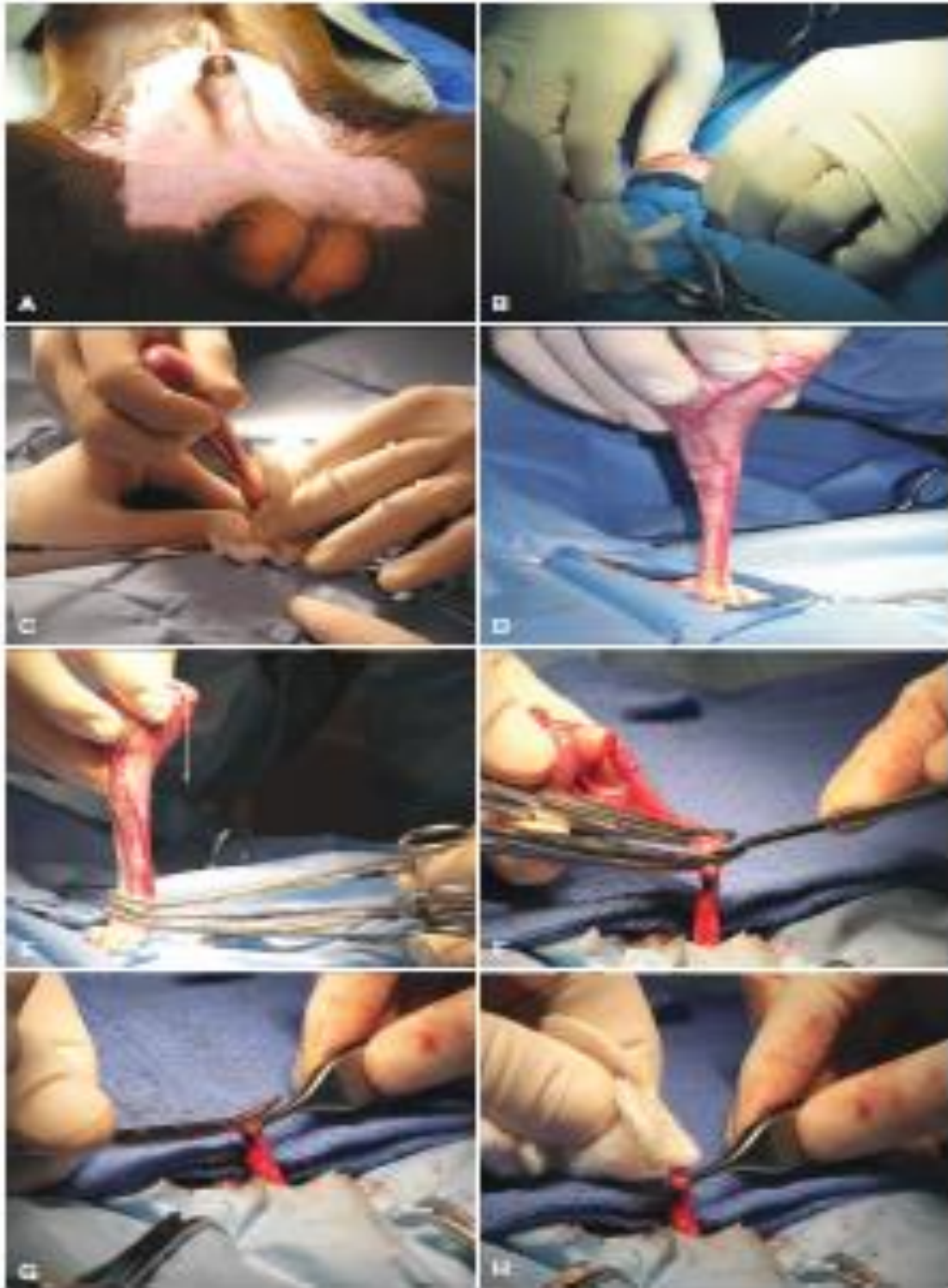

FIGURE 111-7 Closed orchiopexy. **A**, The pre-scrotal region is aseptically prepared. **B**, The testis is pushed ventral into the pre-scrotal region, and a pre-scrotal incision is made over the testis. Pressure is applied to force the testis through the incision. **C**, The testis and spermatic cord are secured from the spermatic cord. **D**, Stopped spermatic cord. **E**, These clips are applied to the spermatic cord. **F**, After two ligatures have been placed (as described in text), the spermatic cord is cut between clips. **G**, Before re-securing the clips, the stump is grasped with thumb forceps. **H**, The stump is checked for hemorrhage before re-securing.

Open Technique

During open castration, the parietal vaginal tunic is incised over the testicle with a scalpel blade, and the opening is extended toward the cord using scissors.

To avoid exposure of testicular parenchyma, the visceral vaginal tunic and shiny tunica albuginea are not incised.

The parietal tunic, cremaster muscle, and ductus deferens and its vessels are separated from the spermatic vascular cord (testicular artery, nerve, and pampiniform plexus).

The three-clamp technique can then be performed on each group of structures using two circumferential ligatures or one circumferential and one transfixation ligature.

The vaginal tunic, cremaster muscle, and ductus deferens and its associated vessels must be ligated to close the peritoneal cavity, which has been entered with this technique.

After the parietal vaginal tunic has been incised, the spermatic cord is not separated into two components. The entire spermatic cord is ligated using the three-clamp technique, and it is then replaced into the parietal vaginal tunic.

The parietal vaginal tunic is closed with a ligature.

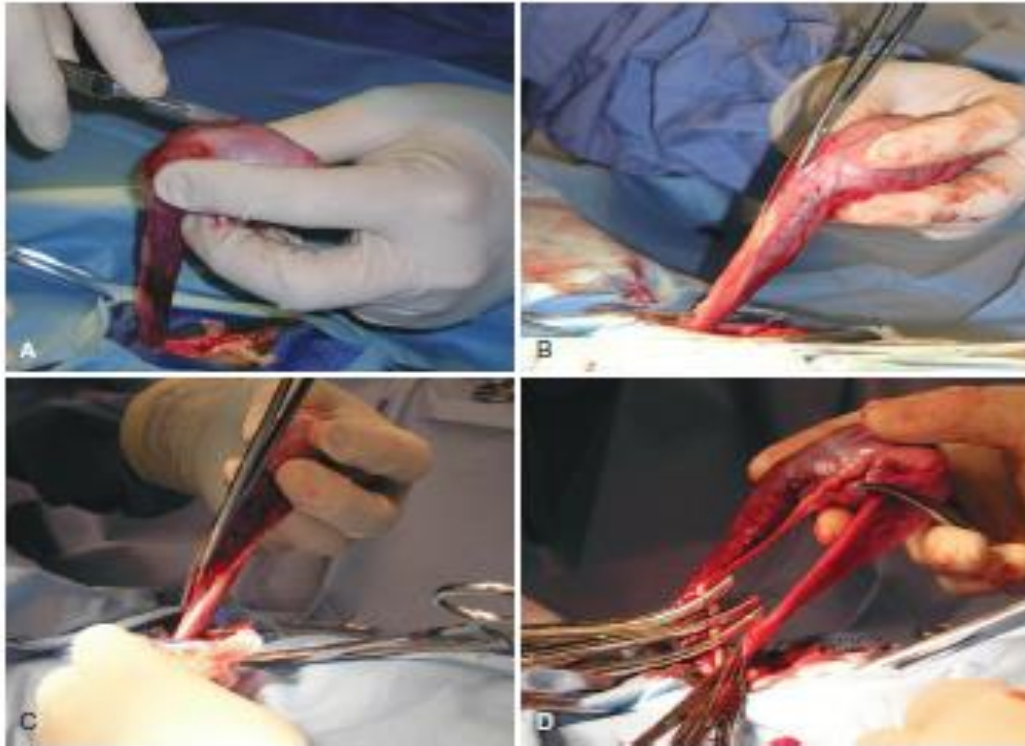

Figure 111-9 Open castric castration. A, The parietal vaginal tunic is incised over the testicle. B, Metzenbaum scissors are used to extend the incision through the parietal vaginal tunic. C, The incision has been extended through the parietal vaginal tunic. D, The parietal tunic, cremaster muscle, and ductus deferens and its vessels are separated from the spermatic vascular cord (testicular artery, nerve, and pampiniform plexus). Clamps are applied to each section.

Feline Orchiectomy

Cats can be positioned in dorsal or lateral recumbency with the hindlimbs pulled forward. The hair over the scrotal sac is plucked free of hair, and the region is Aseptically prepped.

The scrotum is draped within the surgical field.

The testicle is immobilized within the scrotum, and the overlying skin is incised. The incision should be parallel to the scrotal median septum and about half the distance from the septum and the lateral aspect of the scrotum. It should be just big enough to squeeze the testicle through. The testis is pushed through the scrotal incision and grasped.

Overhand Hemostat and Figure of Eight

Hemostat Techniques

Overhand and figure of eight techniques are performed with Halsted mosquito hemostatic forceps.

The figure of eight knot is more secure than the overhand knot; however, it may be more difficult to slide the knot over the hemostat. For both techniques, the spermatic cord should be wrapped around the hemostat close to the tips and to the scrotum. Before hemostat release, the knot is tightened by placing traction between the knot and the hemostat.

Ligation Technique

Two circumferential ligatures are placed around the distal spermatic cord using 3-0 or 4-0 monofilament absorbable suture. A two- or three-clamp technique can be used if necessary. Alternatively, two appropriately sized hemoclips can be placed on each spermatic cord.

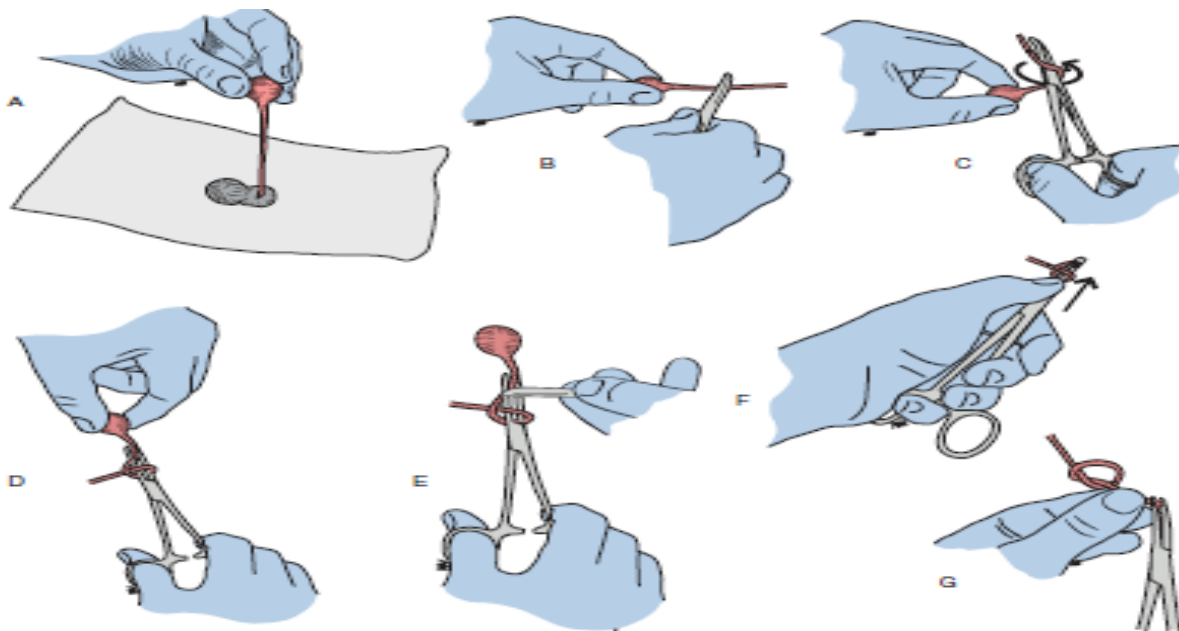
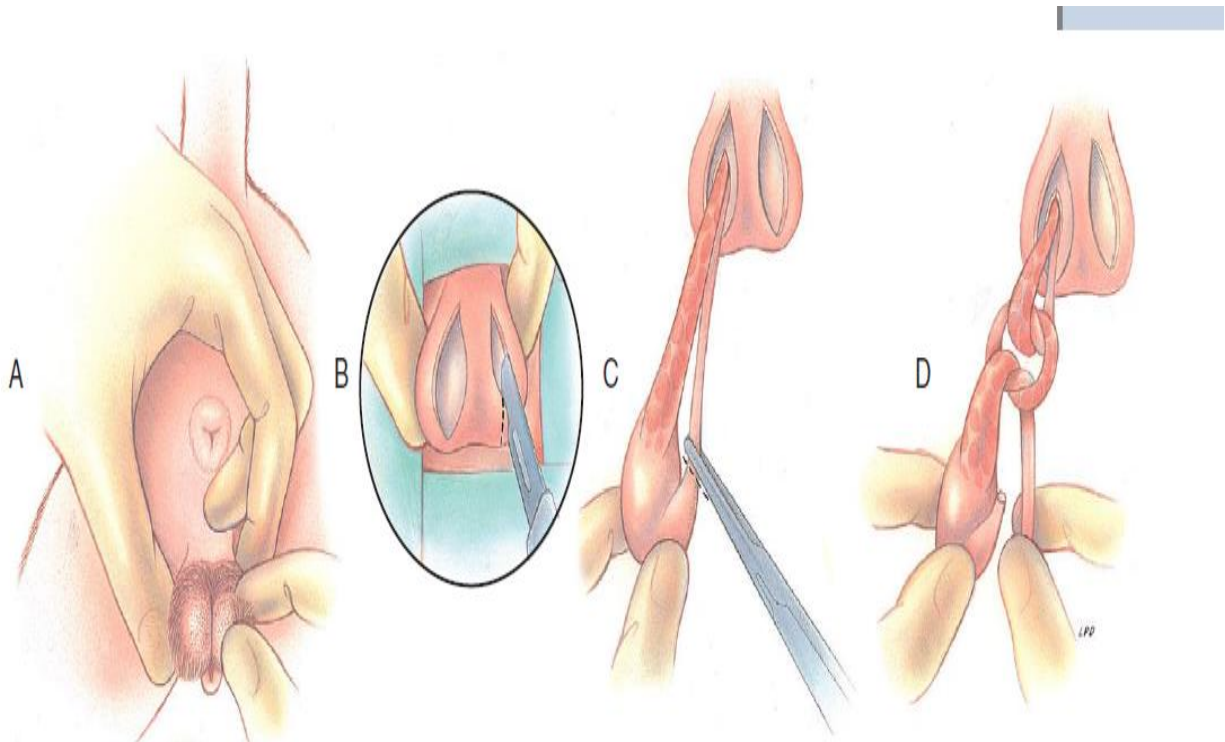


Figure 111-11 Overhand hemostat technique. A, Slow, gentle caudal traction is applied to the testicle until sufficient spermatic cord is present to allow testicle removal. B, A curved hemostat is placed on top of the spermatic cord. C, The spermatic cord is wrapped over the hemostat. D, The distal spermatic cord and testicle are resected. E, The knot is pushed over the tips of the hemostat. F, The knot is tightened by pulling the ends of the hemostat. G, The practitioner ensures the knot is secure.

Square Knot Technique

The square knot technique is an open castration. The parietal vaginal tunic is incised, and the testicle is retracted to stretch the cord. The vaginal tunic, its associated cremaster muscle, and the ductus deferens and its associated vessels are separated from the spermatic vascular cord (testicular artery, nerve, and pampiniform plexus), resulting in two separate structures. These two structures are tied together with two or three square knots (four to six throws), and the spermatic cord is transected distally.

Failure of this technique occurs when slip knots are placed instead of square knots.



Vasectomy

Vasectomy is an additional option for castration in dogs and cats and can be performed through an open caudal midline abdominal approach, abdominal laparoscopy-assisted approach, or prescrotal incision. Both ductus deferens need to be identified; each is double ligated with hemoclips or suture and transected. Vasectomy does not prevent testosterone-dependent diseases or alter undesirable male sex behaviors and characteristics.

SURGICAL COMPLICATIONS

Complications of canine castration include

- 1- Infection
- 2- scrotal bruising
- 3- Hemorrhage
- 4- Swelling
- 5-scrotal hematoma