

# Stomach

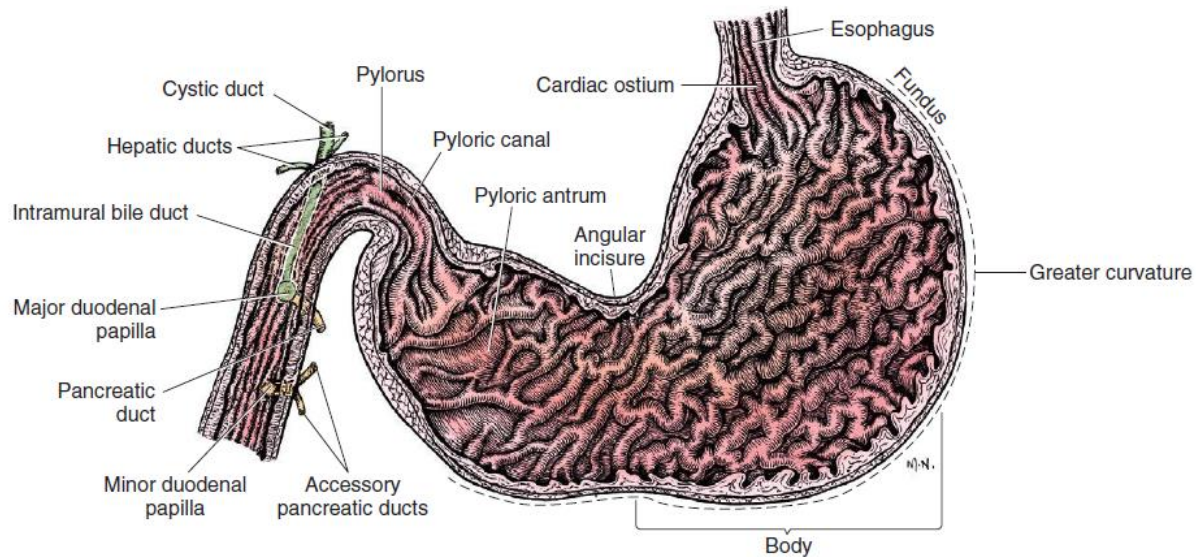
## Anatomy of the Stomach

Grossly, the stomach is divided into the

- 1- cardia,
- 2- fundus,
- 3- body,
- 4- pyloric portions.

The greater curvature of the stomach is convex and connects the cardia and pylorus and incorporates the fundus.

The lesser curvature also connects the cardia and pylorus but is much shorter than the greater curvature.



The arterial blood supply of the stomach originates from the celiac artery, a direct branch from the aorta.

The celiac artery divides into its component parts, the splenic, hepatic, and left gastric arteries

## Gastric Layers

The stomach wall is composed of four distinct layers

The serosa, muscle, submucosa, and mucosa.

The muscular composition of the stomach is divided into three layers. The longitudinal layer passes longitudinally from the esophagus to the duodenum along the greater curvature of the stomach.

The inner circular layer begins at the cardia, where it forms part of the gastroesophageal (cardiac) sphincter.

The oblique muscle fibers, which are over the body and fundic

The submucosa is composed of a thin elastic layer of areolar tissue and serves as the critical holding layer during surgical closure of gastric incisions.

The mucosal layer is made up of columnar surface epithelium, a glandular lamina propria, and a lamina muscularis mucosa.

## Approach

Gastric surgery of the small animal patient is most commonly performed through a **ventral midline abdominal incision that extends from the xiphoid process of the sternum to a point caudal to the umbilicus and, in many instances, to the cranial extent of the pubis.**

**paracostal approach is achieved by making a curved incision approximately 2 cm caudal to the last rib.** The underlying muscle layers, including the external and internal abdominal oblique and transversus abdominis muscles, are split longitudinally along the direction of the muscle fibers.

## Minimizing Contamination

Minimizing the risk of and consequences of gastric content spillage is achieved by carefully packing off the stomach from the remaining abdomen using laparotomy sponges moistened with warm sterile saline solution.

Stay sutures of 2-0 or 3-0 monofilament suture on a taper needle are placed surrounding the area of interest using large full-thickness bites that will not tear through the gastric wall and are grasped by hemostatic forceps to elevate the stomach before entry into its lumen

## **GENERAL SURGICAL TECHNIQUES**

### **Gastrotomy**

The stomach is isolated from the remainder of the abdomen with moistened laparotomy sponges, and stay sutures are placed at the appropriate points. A gastrotomy is performed on the ventral surface of the stomach midway between its lesser and greater curvatures in the area with the least vascularity.

The underlying reason for the gastrotomy dictates the location and length of the incision (see section on gastric foreign body removal). Closure of the gastrotomy incision is accomplished in the same fashion as described for closure of a gastric biopsy described above.

### **Gastropexy**

Gastropexy is the creation of a permanent adhesion of the stomach to the adjacent body wall. Gastropexy is most commonly performed for prevention of gastric dilatation and volvulus but is also used in the treatment of hiatal hernia.

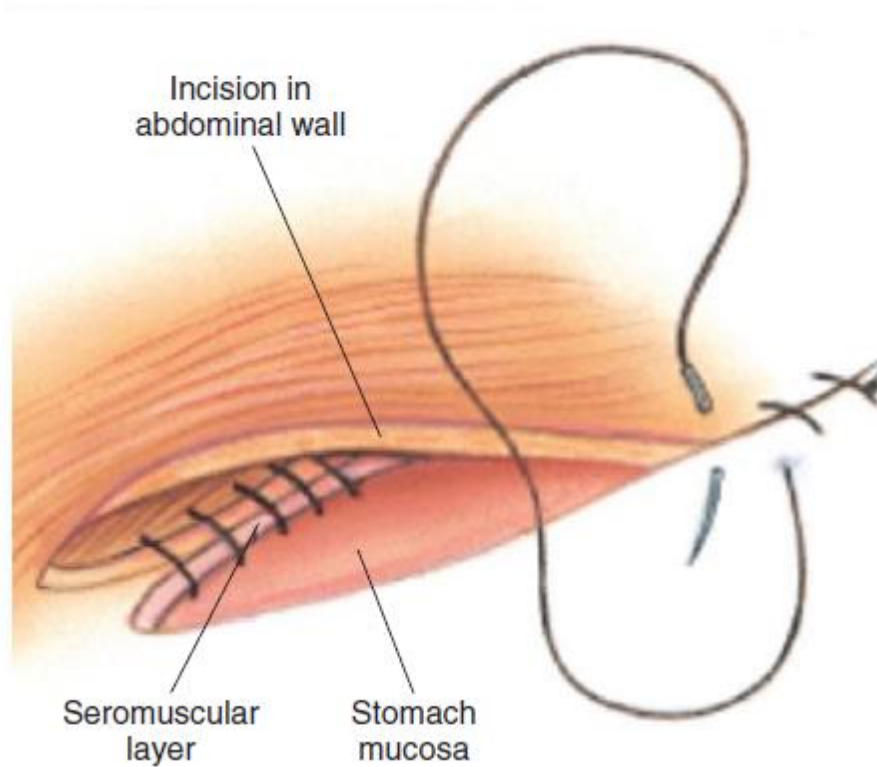
Gastropexy for prevention of gastric dilatation and volvulus is performed between the pyloric antrum and the right abdominal wall.

#### **1- Incisional Gastropexy**

Incisional gastropexy for prevention of gastric dilatation and volvulus is performed by creating a 4- to 5-cm seromuscular incision in the gastric antrum either parallel or perpendicular to the long axis of the stomach. Care should be taken to avoid penetration of the gastric mucosa.

A second incision is made through the peritoneum and the transverse abdominis muscle on the lateral or ventrolateral right abdominal wall approximately 2 to 3 cm caudal to the last rib.

Gastric and abdominal wall incisions are apposed using 2-0 monofilament absorbable suture in a simple continuous suture pattern



## 2- Circumcostal Gastropexy

The seromuscular flap may be single hinged. When a single-hinged flap is used, it is based from the lesser curvature of the stomach and undermined below the level of the muscularis layer, taking care not to penetrate the gastric lumen.

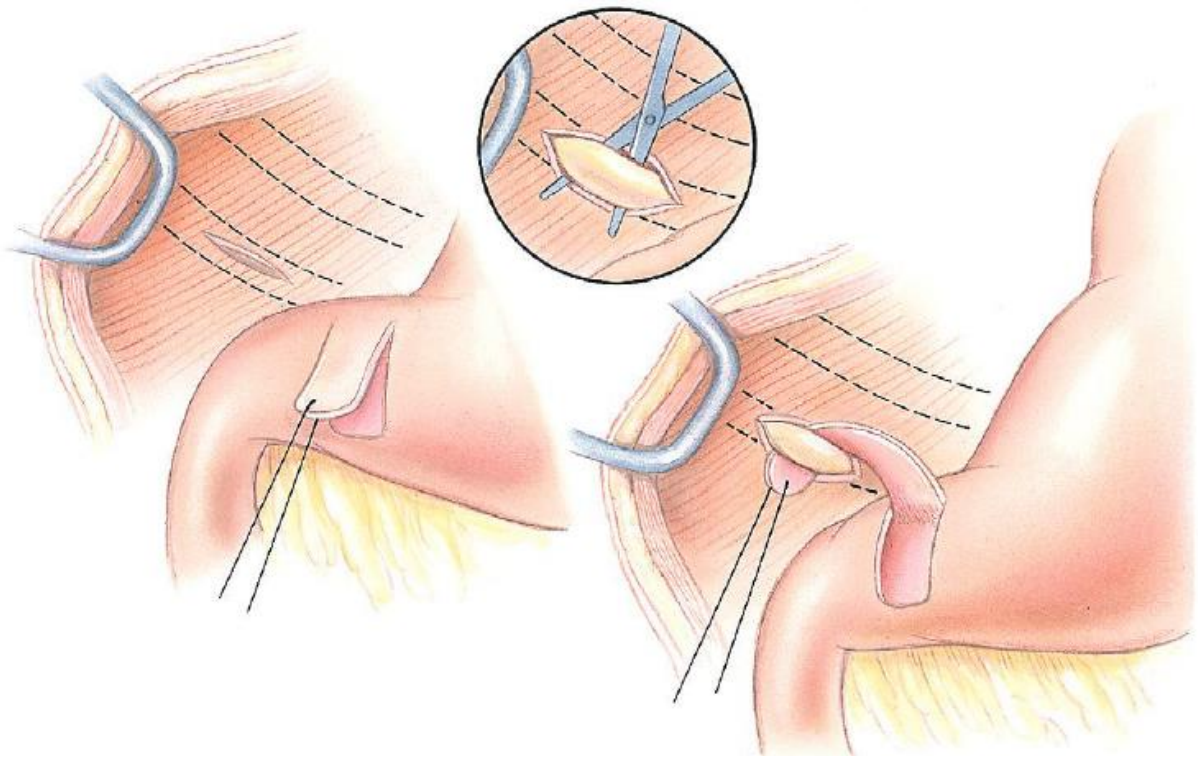
A 5- to 6-cm incision is made directly over the eleventh or twelfth rib at the level of the costochondral junction.

A plane of blunt dissection is then established circumferentially in close association with the rib.

Care must be taken to avoid creation of pneumothorax or fracture of the rib; both are reported complications of this procedure.

The seromuscular gastric flap is then passed cranial to caudal through the tunnel surrounding the rib; stay sutures placed in the leading edge of the flap facilitate passage around the rib.

The seromuscular flap is sutured back to its origin using 2-0 or 3-0 absorbable suture material.



### **3- Gastrocolopexy**

Creation of a suture line between the greater curvature of the stomach and the transverse colon has been described to prevent recurrence of gastric dilatation and volvulus.

Gastrocolopexy as reported does not include incision into the seromuscular layer of either the stomach or the colon; instead, the surfaces are scarified and then apposed with nonabsorbable sutures.

## **Pyloromyotomy and Pyloroplasty**

Pyloric surgical techniques are focused on removing outflow obstruction and normalizing gastric outflow. Several techniques have been described, including the Fredet-Ramstedt pyloromyotomy, Heineke-Mikulicz pyloroplasty, and Y-U pyloroplasty.

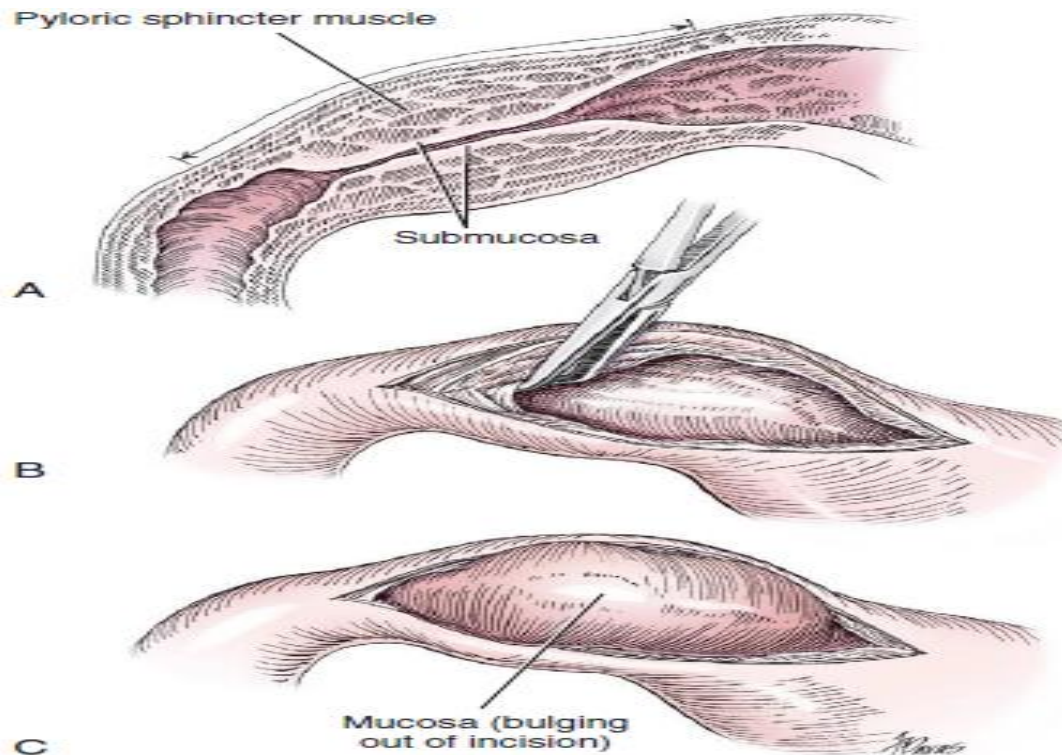
### **Fredet-Ramstedt Pyloromyotomy**

Fredet-Ramstedt pyloromyotomy is performed by making a longitudinal incision through serosa and muscularis of the ventral pylorus.

The incision should be centered over the pylorus and extend 1 to 2 cm.

When performed correctly, the gastric mucosa is not penetrated, its submucosal surface should protrude through the incision.

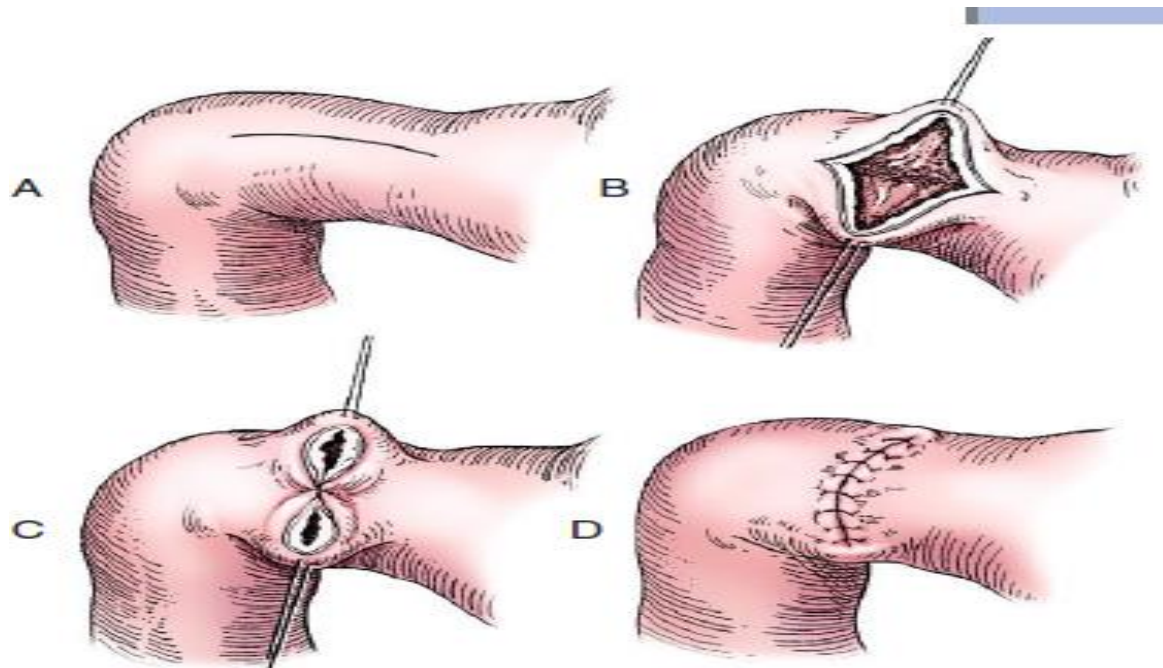
This partial-thickness incision is left open, permitting enlargement of the pylorus in cases in which restriction is limited to the serosa or muscularis.



### **Heineke-Mikulicz Pyloroplasty**

Heineke-Mikulicz pyloroplasty is similar to pyloromyotomy in that a longitudinal incision is made in the ventral surface of the pylorus; however, the incision is created full thickness and then closed transversely.

Stay sutures can be placed in the middle of either side of the longitudinal incision and retracted to provide apposition for the transverse closure, stay sutures can be placed at each end of the incision and pulled together to provide the same effect. Closure is achieved with 2-0 or 3-0 absorbable monofilament suture material in an appositional pattern.



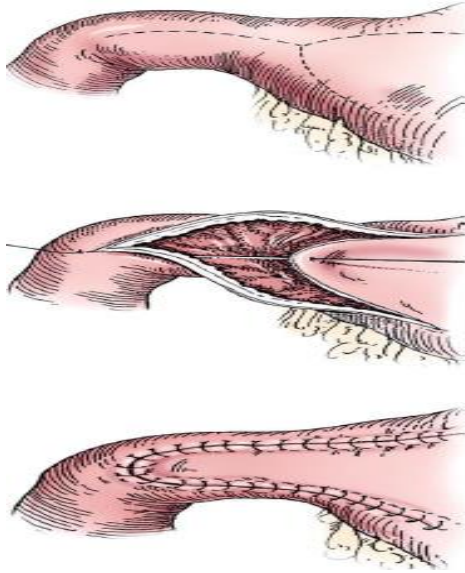
### **Y-U Advancement Pyloroplasty**

Y-U advancement pyloroplasty increases pyloric outflow tract diameter by advancing a portion of the pyloric antrum into the region of the pyloric sphincter. A Y-shaped full-thickness incision is centered over the pylorus.

The incision for the body (or main stem) of the Y is made through the antimesenteric border of the duodenum, and the incisions for the arms of the Y extend into the pyloric antrum .

The arms of the Y should curve slightly to form a U-shaped flap instead of a sharp V to maximize vascular supply to the enclosed tissue.

The U-shaped flap is then advanced forward using stay sutures at its tip and sutured into the most aboral portion of the incision at the duodenum using 2-0 absorbable monofilament suture material in an appositional pattern.



## Gastroduodenal Anastomosis

Pylorectomy with gastroduodenal anastomosis (Billroth I) is performed in animals with pyloric outflow obstruction that cannot be treated with routine pyloroplasty techniques.

Indications include neoplasia confined to the pyloric region, ulceration of the outflow tract, and some cases of pyloric hypertrophy.

When neoplasia is suspected, a 1- to 2-cm margin of normal tissue should be removed with the abnormal tissue.

The bile duct, pancreatic ducts, and vascular supply to the stomach and duodenum must be identified before any surgical excision.

The bile duct is best identified by manual expression of the gallbladder: bile can be detected as it descends through and dilates the bile duct as it approaches the duodenum.

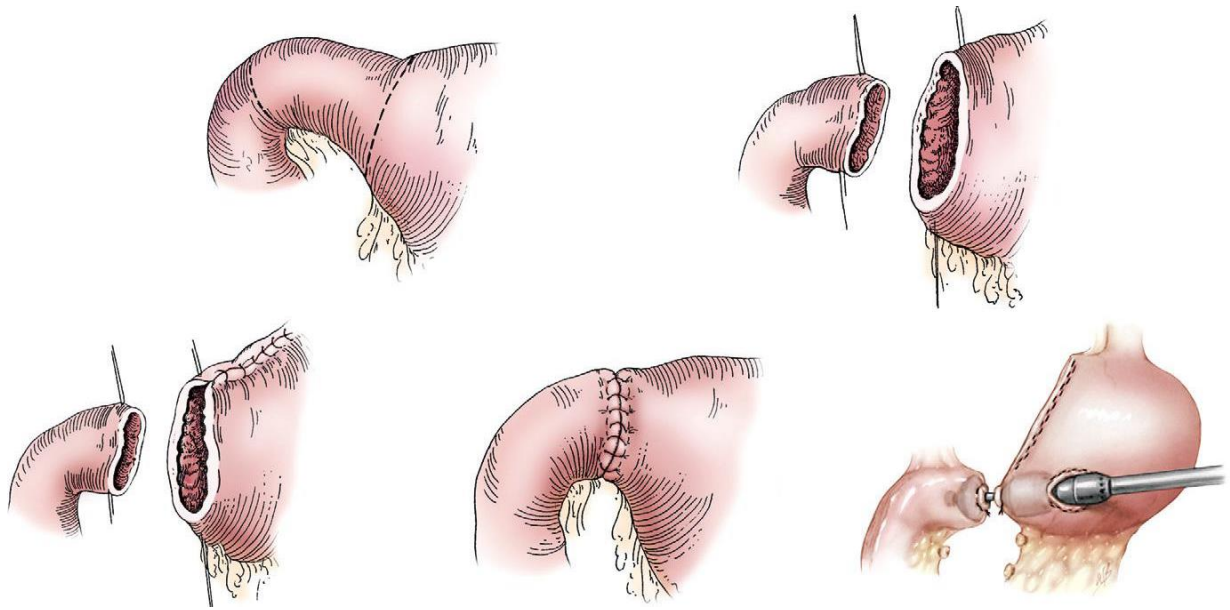
Stay sutures are placed in the duodenum and stomach to facilitate retraction and minimize potential leakage.

After making sure the area is packed off from the rest of the abdomen with laparotomy sponges, the pylorus is removed with Metzenbaum scissors or a scalpel.

If a significant discrepancy in lumen diameter is created by this resection, the surgeon may choose to incise the antimesenteric border of the duodenum to

increase its diameter or close a portion of the gastric antrum to narrow gastric diameter to facilitate anastomosis.

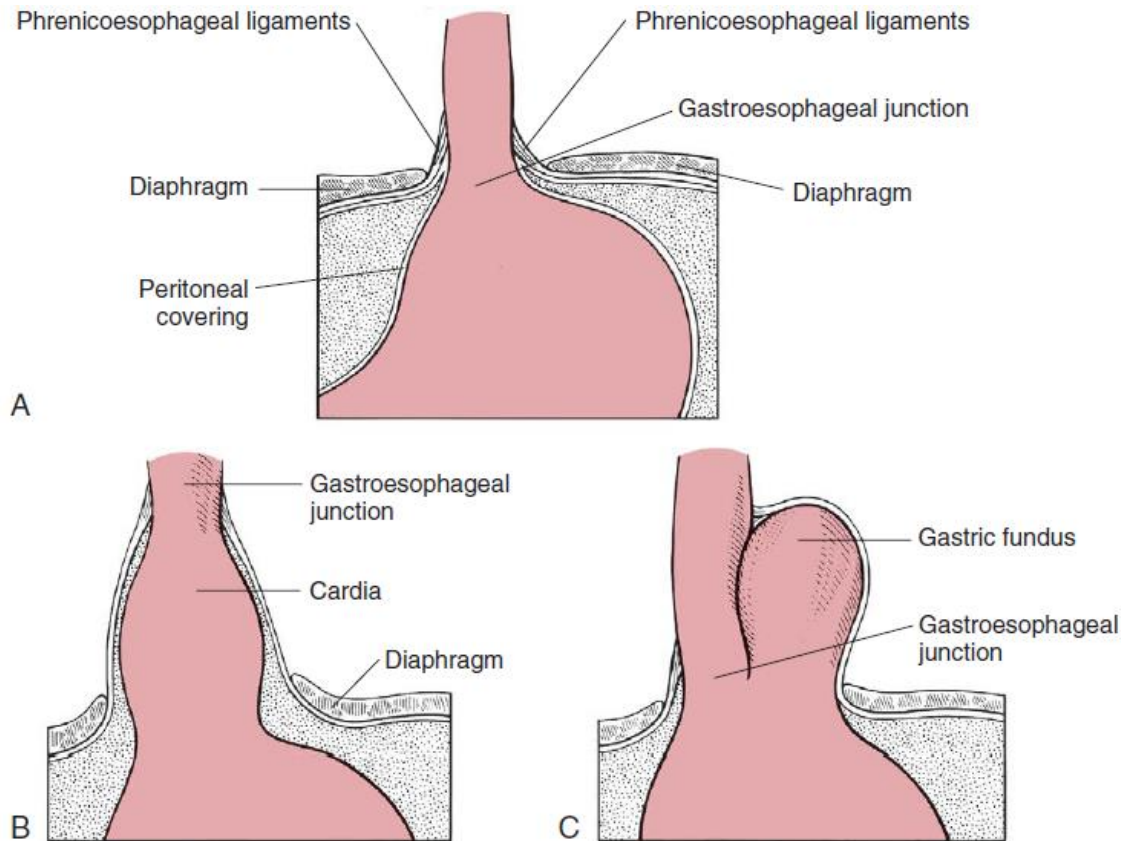
End-to-end anastomosis of the stomach and duodenum is performed with a one- or two-layer appositional pattern using a simple interrupted or simple continuous pattern of 2-0 or 3-0 absorbable monofilament suture.



## **SPECIFIC DISEASES**

### **Hiatal Hernia**

The esophageal hiatus is formed by the musculature of the medial portion of the lumbar crus of the diaphragm.



## Clinical Findings

Clinical signs of hiatal hernia include regurgitation, hypersalivation, vomiting, dysphagia, respiratory distress, anorexia, and weight loss.

In most cases of congenital hiatal hernia, clinical signs develop between 2 and 4 months of age, and the onset of clinical signs may be related to weaning of puppies from a liquid to a solid diet. It is important to keep in mind, however, that clinical signs have also been reported earlier and later in life.

## Surgical Correction

Several surgical techniques have been described for treatment of hiatal hernias. Diaphragmatic hiatal reduction (phrenoplasty), esophagopexy, and left-sided gastropexy are the techniques used most commonly, either alone or in combination.

## **Gastric Foreign Body**

Foreign bodies reported in dogs include plastic, bones, sharp objects (e.g., fishhooks), wood, and organic material.

In some instances, the ingested material changes after ingestion, as is the case with some wood glue compounds, and becomes an obstructive foreign body within the stomach

### **Clinical Findings**

The clinical signs of gastric foreign body are vomiting and, in some instances, regurgitation secondary to esophageal irritation from the vomiting.

Abdominal distension may be evident if pyloric outflow obstruction is present, and abdominal pain may be noted in patients with obstruction, perforation, or ulcer.

### **Diagnostics**

The imaging technique of choice for visualization of gastric foreign bodies is controversial.

### **Surgery**

When a foreign body has been detected in the stomach, surgical removal should occur in a timely manner.

## **Gastric Ulceration**

### **Clinical Findings**

Clinical signs of gastric ulceration vary, but vomiting and anorexia are reported frequently. In some instances, digested blood, which has a “coffee grounds” appearance.

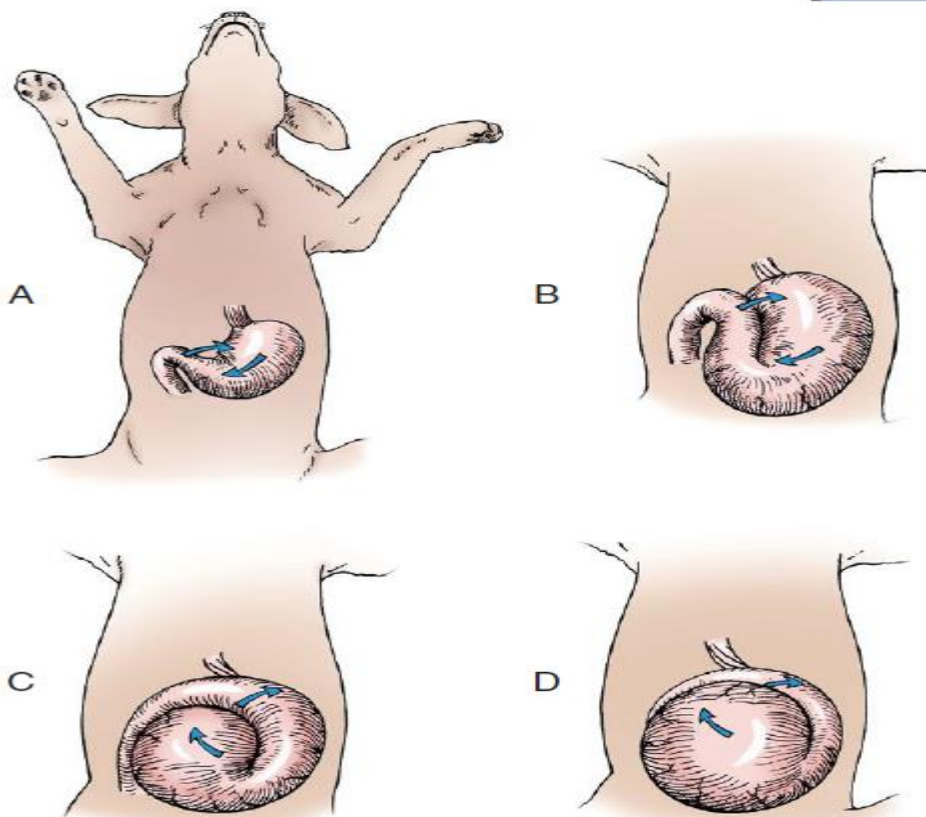
### **Surgery**

Surgical treatment of gastric ulcers includes removal of the ulcerated area and full-thickness biopsy of the lesion for histopathologic evaluation.

## Gastric Dilatation and Volvulus

Gastric dilatation and volvulus is a life-threatening syndrome reported most commonly in large-breed, deep-chested dogs in which the stomach rotates on its axis, trapping air within its lumen.

Trapped air increases intragastric pressure, which, in turn, decreases venous flow through the abdomen by direct compression. Portal hypertension, systemic hypotension, and cardiogenic shock result.



The stomach during gastric dilatation and volvulus. **A**, The pylorus moves ventrally and toward the left body wall. **B**, The stomach becomes more distended as the rotation continues. **C**, In a 180-degree torsion, the pylorus rests to the left of the midline cranial to the body of the stomach. This malposition creates a fold in the stomach. **D**, Gastric distension continues to worsen over time as outflow from the stomach is prevented in either direction

## **Etiology**

The cause of gastric dilatation and volvulus is not completely understood. Specific risk factors for gastric dilatation and volvulus identified in dogs include purebred large or giant breed, an increased thoracic depth-to-width ratio, history of gastric dilatation and volvulus in a first-degree relative, feeding fewer meals per day, eating rapidly, aggressive or fearful temperament, decreased food particle size, increased hepatogastric ligament length, and exercise or stress after a meal.

## **Clinical Findings**

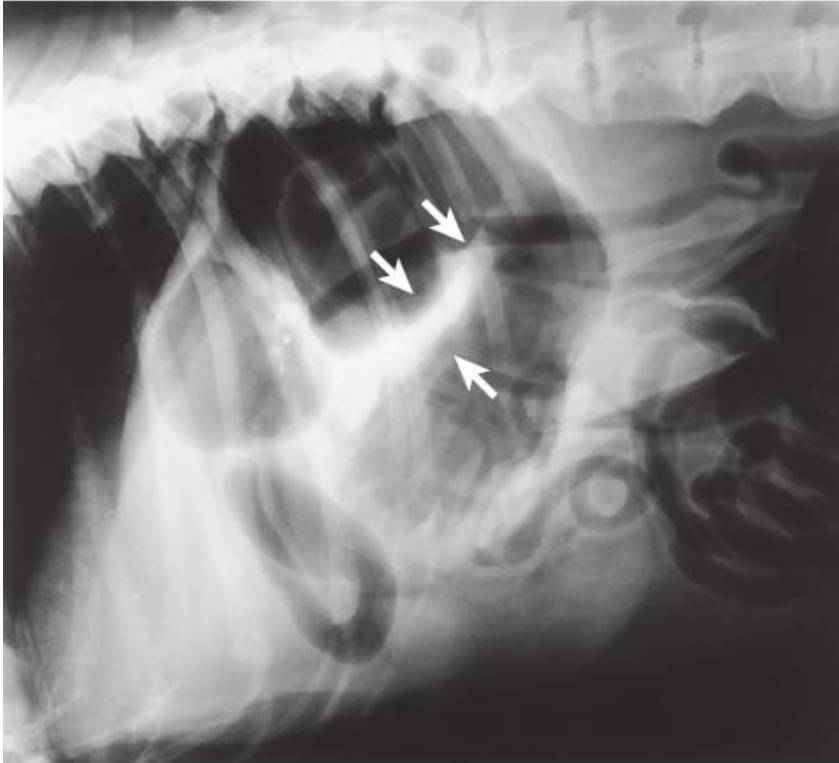
Clinical signs of gastric dilatation and volvulus include abdominal distension, unproductive vomiting or retching, restlessness, and hypersalivation.

## **Diagnostics**

Radiographs. When necessary, radiography is done with the dog in right lateral recumbency to confirm the diagnosis.

Animals with gastric dilatation and volvulus have pyloric malposition with entrapment of air within the pylorus.

The finding of a “double bubble,” “reverse C,” or “Popeye sign” is the result of seeing air in the pylorus that is separated from air in the body of the stomach by a soft tissue density.



## Surgery

The goals of surgery are to reposition the stomach, remove devitalized or necrotic tissue, and create a permanent adhesion between the pyloric antrum and right body wall.

Before attempting de-rotation of the stomach, it should be decompressed completely. This may be achieved by passage of an orogastric tube by a nonsterile assistant or via needle decompression by the surgeon.

The advantages of orogastric tube intubation include the ability to remove food and air with minimal risk of contamination of the abdominal cavity. Generally, even if an orogastric tube cannot be passed before surgery, an assistant can pass the tube intraoperatively with the aid of the surgeon, who manipulates the cardia as the tube enters the stomach.

Food and liquids can reflux around a large-bore tube and into the esophagus, so the endotracheal cuff should be inflated appropriately and the esophagus suctioned if reflux occurs. After the stomach is decompressed, the surgeon must identify the pylorus and retract it toward the right side of the abdomen while using the opposite hand to push the body of the stomach dorsally.

Gastric rotation of 90 to 360 degrees has been reported, with rotation of 180 to 270 degrees most common.