

Large Intestinal Surgery

Congenital Abnormalities

Congenital abnormalities of rectum and anal canal are common in pigs, goats, sheep, cattle, and less common in horses, and it is also reported in human.

These abnormalities includes:

- 1- Atresia ani.
- 2- Atresia recti.
- 3- Recto-vaginal fistula.

Atresia ani:- in Atresia ani the anal membrane persist and not ruptured. In uncomplicated cases of Atresia ani there usually a depression where the anus should be and the sphincter is normal.

Clinical sings:-

1. The animal with Atresia ani whine and exhibits tenesmus.
2. The anus is absent.
3. Bulging of the perineum due to accumulation of feces.

Surgical treatment:-

1. The operation is performed under local infiltration.
2. A circular or cruciate incision applied on the bulge where the anus should be, and by careful blunt dissection the blind end of the rectum is exposed.
3. This is grasped gently with a forceps to pull it caudally to the newly created anal orifice.
4. The blind end of the rectum is then opened, and a series of sutures are inserted around the periphery of the skin and mucous membrane.

Atresia recti (Atresia ani et recti):-

when the blind end of the rectum is

situated too far cranially, it has the same clinical signs of atresia ani, but there is no bulging of the anal site by the tenesmus of the animal or when pressure was applied on the abdomen

Surgical treatment:-

The blind end of the rectum must be identified and isolated through the abdomen.

1. After the rectum is mobilized, a tunnel is made bluntly through the pelvic canal.
2. The rectum is then drawn through the tunnel and secured, incised, and sutured as in case of atresia ani.

There is another method for treatment of atresia recti by **colostomy**, it is accomplished by laparotomy and the blind end of the colon is brought out through the laparotomy incision and fixed with the skin or through another small skin incision away from the laparotomy incision, then the blind end of the colon is opened and fixed with the skin incision.

The prognosis of this condition always not good.

Rectovaginal Fistula:- Presence of duct communicate between the rectum and vagina.

This is seen in female, rarely in males , a rectourethral fistula may be present.

Clinical signs:-

1. Feces may be passed from the vagina.
2. In those rare cases of rectourethral fistula in the male, feces stained urine will be passed.

Surgical treatment:-

After making a perineal midline incision, the communicating tract between rectum and vagina is identified by dissection. The two structures are then separated, and the roof of the vagina is closed in a linear fashion.

Rectal prolapse:-

This refers to eversion of the caudal portion of the rectum through the anus, it most commonly occurs in young ages.

Causes of rectal prolapse:-

1. Heavily parasitized animals, parasites irritating the intestine which cause diarrhea, tenesmus, and subsequent prolapse.
2. Rectal prolapse may accompany intestinal foreign bodies or Neoplasia.
3. Rectal prolapse may occur during or following parturition or as a complication of prostatic disease.
4. Congenital weakness of the perineum.

Clinical signs:-

1. A cylindrical mass of varying length protrudes from the anus.
2. The exposed rectal mucosa may be ulcerated or necrotic if the prolapse has been present for some time.
3. The protruding mass often seems to be insensitive, and its manipulation causes no discomfort.
4. True rectal prolapse can be **differentiated** from an intussusception of small intestine, colon or cranial portion of rectum that has passed through the anus by gently inserting a probe between the prolapsed anus and anal sphincter. The probe can be passed if an intussusception has occurred, but not if a prolapse is present

Treatment:-

1. The initiating lesion must be corrected to provide permanent relief.
2. When the prolapse is small, the tissues may be replaced following application of 5% alum or a saturated solution of sugar.
3. A purse-string suture around the anus may be sufficient to prevent recurrence. The suture must be loosened periodically for defecation.

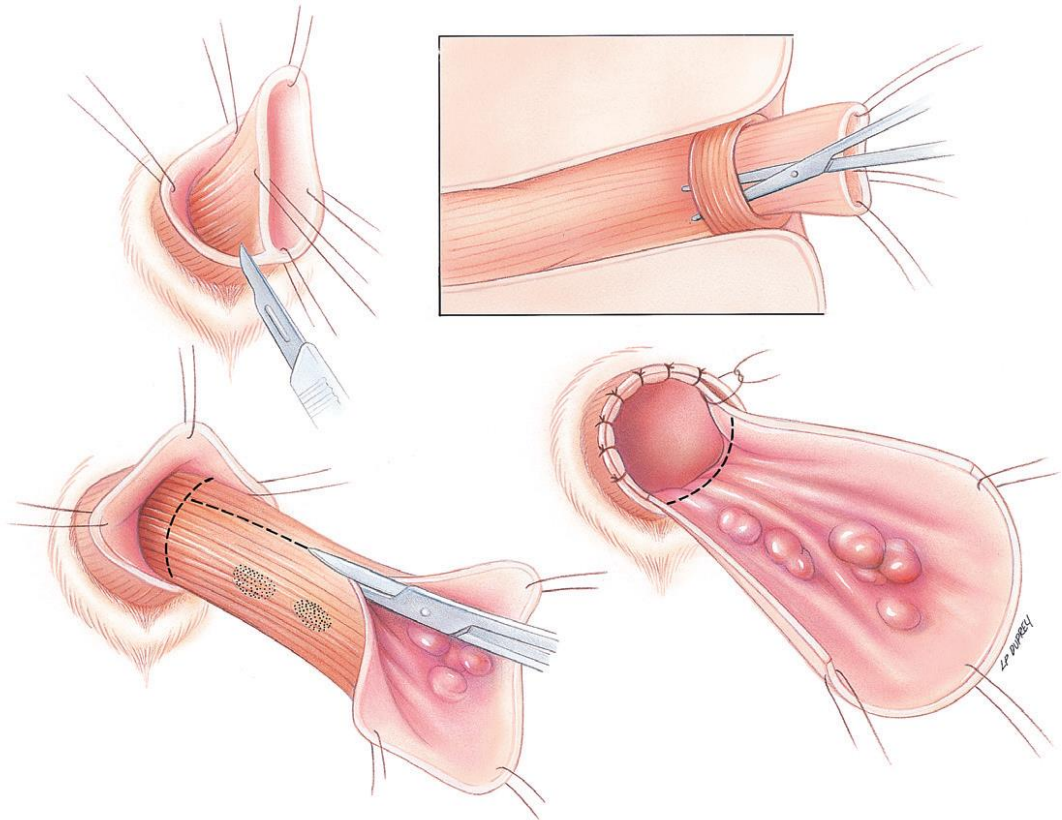
4. If the operation is performed under epidural anesthesia, straining following reduction of the prolapse will be avoided for several hours.
5. The periodic application of a local anesthetic ointment further reduces the stimulus to strain

Amputation of rectal prolapse:-

When the prolapse has been longstanding and the tissues become necrotic, the prolapsed portion of the rectum should be amputated.

Surgical procedure:-

1. The operation can be performed under general or epidural anesthesia.
2. The patient should be positioned in ventral recumbency with the hind legs over the end of the table and the tail secured over the back.
3. A probe is inserted into the rectal lumen to serve as a guide.
4. Apply 3 horizontal mattress stay sutures (at 12 o'clock, 5 o'clock, and 8 o'clock position) through all layers of the prolapse just cranial to the proposed transaction site. These suture should enter the rectal lumen with the needle being deflected by the probe before being passed through the rectal tissue again.
5. Transect the traumatized tissue in stages caudal to the stay sutures.
6. After each stage of the resection, anatomically appose the transected edges with simple interrupted sutures (using 3/0 or 4/0 absorbable suture material). Space the sutures approximately 2mm apart and 2mm from the cut edge.
7. Remove the sutures and gently replace the anastomotic site in the pelvic or anal canal.
8. Apply purse-string suture around the anus if postoperative tenesmus is expected.



Anal sac infection and impaction:-

Anal sac impaction is an abnormal accumulation of anal sac secretions secondary to inflammation (anal sacculitis), infection (anal sac abscess), or obstruction of the duct.

Anal sac diseases include impaction, infection, abscessation, and neoplasia. They are paired, lying between fibers of the anal sphincter. They serve as reservoirs of their secretions which is malodorous, pastelike consistency with dark brown color.

Clinical sings:-

1- Impaction causes the dog to lick or bite the area or slide the anus on the ground in an attempt to relieve the irritation and pain produced by inflammation and pressure. This will lead to trauma and excoriation of the skin and perhaps abscessation of the anal sacs.

2- The anal sacs are examined by introducing a lubricated gloved index finger into the anus slowly and gently. The distended sacs are readily felt below and on each side of the anus. They should be massaged gently

and evacuated by squeezing the sacs gently between index finger and thumb.

3- When the wall of the anal sac is infected, the contents usually are purulent and may be blood-streaked.

4- Chronic infection of the anal sac caused the dog to lick the perineum frequently.

Treatment:-

Unless infection is present periodic evacuation of the sacs is sufficient. If infection appear to be present a sample of the contents should be cultured and a suitable antibiotics is instilled into them. If this fails, the sacs should be surgically removed.

There are 2 surgical techniques for removal of the sacs (saccullectomy)

A. Closed technique:-

1. Insert a small probe, hemostat, or balloon-tip catheter into the orifice of the anal sac duct. Advance the instrument or inflate the balloon with saline until the lateral extent of the sac is identified. Other alternatives are infusion of wax, plaster of paris, or insertion of cotton thread into the sacs.
2. Make a curve linear incision over the anal sac.
3. Dissecting directly against the anal sac, separate the internal and external anal sphincter muscle fibers from the sac with small scissors.
4. Avoid excising or traumatizing the muscles or the caudal rectal artery medial to the duct.
5. Continue dissecting to free the sac and duct to its mucocutaneous junction at the anal canal.
6. Place a ligature around the duct at the mucocutaneous junction using 4/ 0 absorbable suture.
7. Excise the anal sac and duct, then inspect for completeness of removal.

8. Control hemorrhage with ligatures, electrocoagulation, or pressure.
9. Lavage the tissue thoroughly.
10. Appose the subcutaneous with 4/0 absorbable suture using interrupted pattern.
11. Appose the skin with 3/0 or 4/0 nonabsorbable suture.

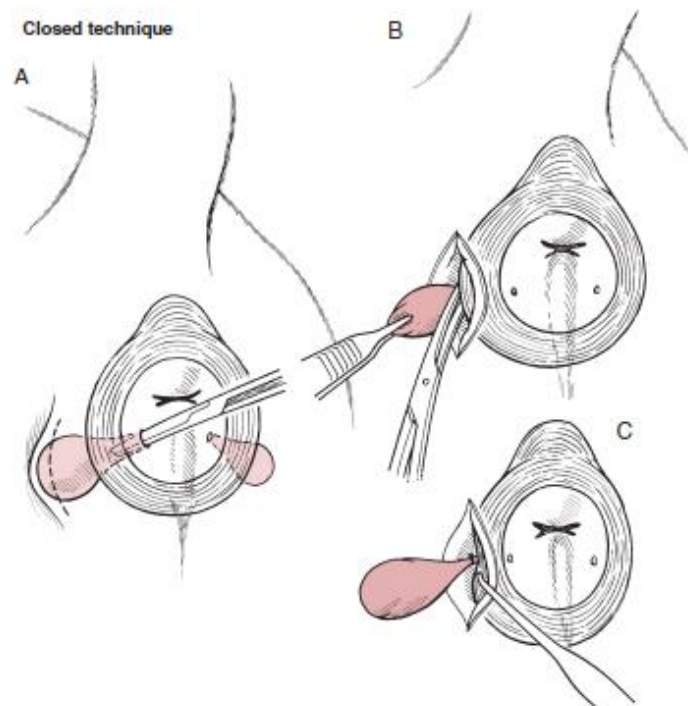


FIG 20-139. Closed technique for anal saccullectomy. **A**, Locate the anal sacs at the 4 o'clock to 5 o'clock and 7 o'clock to 8 o'clock positions between the internal and external anal sphincter muscles. Insert a small probe, hemostat, or balloon-tip catheter into the anal sac. Dashed line indicates incision location. **B**, Make an incision at the lateral aspect of the anal sac and carefully dissect the sac from the sphincter muscle fibers. **C**, Ligate the duct near the orifice.

B- Open technique:-

1. Place a scissors blade or groove director into the duct of the anal sac.
2. Apply medial traction on the duct while incising through the skin, subcutaneous tissue, external anal sphincter, duct and sac. Continue the incision to the lateral extent of the anal sac.
3. Elevate the cut edge of the sac and use small scissors to dissect the sac free of its attachment to muscle and surrounding tissue.

4. Complete the procedure the same as for a closed technique.

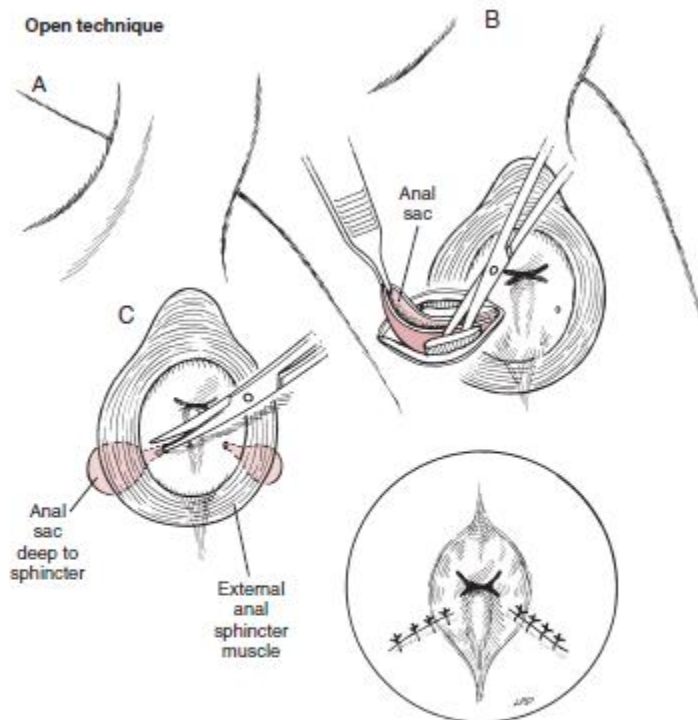


FIG 20-140. Open technique for anal saccullectomy. **A**, Insert the blade of the scissors into the sac and incise through the skin, subcutaneous tissues, external anal sphincter, and anal sac. **B**, Elevate the cut edge of the sac and dissect it from the anal sphincter. **C**, Appose the sphincter, subcutaneous tissues, and skin.

Postoperative care:-

1. Systemic analgesics should be given as necessary.
2. The perianal area should be kept clean, and an Elizabethan collar or similar restraint device should be used to prevent the animal from licking the sites.
3. Food and water may be offered 8-10 hours postoperatively if no vomiting has been noted.
4. A stool softener may be added to the food for 2 to 3 weeks.
5. The surgical site should be monitored for signs of infection or drainage, and the rectum and perianal area should be palpated for evidence of stricture when sutures are removed at 7 to 10 days.
6. Fecal continence may be impaired during the healing process, but usually returns to normal within several weeks.

Closed technique for anal saccullectomy

- A. locate the anal sacs at the 4 o'clock to 5 o'clock and 7 o'clock to 8 o'clock positions between the internal and external anal sphincter muscles, insert a small probe, hemostat, or balloon- tip catheter into the anal sac. Dashed lines indicates incision location.
- B. Make an incision at the lateral aspect of the anal sac and carefully dissect the sac from the sphincter muscle fibers.
- C. Ligate the duct near the orifice.

Open technique for anal saccullectomy

- A. Insert the blade of scissors into the sac and incise through the skin, subcutaneous tissue, external anal sphincter, and anal sac.
- B. Elevate the cut edge of the sac, and dissect it from the anal sphincter.
- C. Appose the sphincter, subcutaneous tissue, and skin