

Bladder

ANATOMY

The bladder lies within the peritoneal cavity and is attached to the abdominal wall via loose, double-layer peritoneal ligaments.

The ventral median ligament, which can be cut before cystotomy, is a very thin structure connecting the bladder to the linea alba and pelvic symphysis.

In fetuses, this ligament contains the **urachus**.

The lateral ligaments of the bladder attach to the pelvic walls and contain fat along with the distal portion of the ureter and umbilical artery on each side.

The lateral ligaments should be identified and avoided during dissection around the bladder to prevent damage to the ureters.

The bladder varies in size, depending on the volume it contains.

The position of the bladder is lying within the pelvic canal when empty.

The fully distended bladder located within the pelvic canal.

In male animals, **the deferent ducts pass dorsal to the bladder**; in females, the cervix and body of the uterus are adjacent to the dorsal bladder.

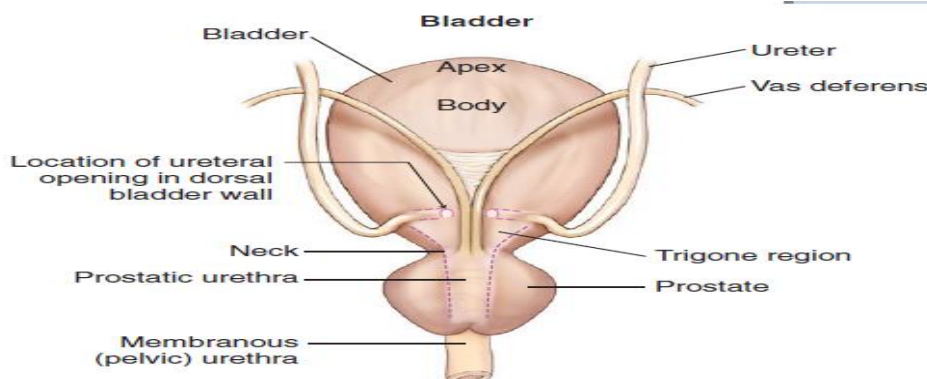
The bladder has an apex, body, and neck.

The bladder consists of **mucosa composed of transitional epithelial cells**, and submucosa, which contains connective tissue.

The normal bladder has a relatively thin wall but becomes thickened when diseased. The serosa is the outermost layer of the bladder.

Blood Supply The vascular supply also enters the bladder dorsally.

The caudal vesical artery is the major arterial supply to the bladder.



DIAGNOSTIC TECHNIQUES

- 1- Cystocentesis
- 2- Diagnostic Imaging
 - a- Bladder ultrasonography
 - b- abdominal radiographs (Contrast radiography)
 - c- Computed tomography (CT)
- 3- Catheter Biopsy
- 4- Cystoscopy (laparoscopic-assisted cystoscopy)

SURGICAL BLADDER CONDITIONS

Bladder Rupture

The bladder rupture may occur secondary to

- 1- trauma
- 2- severe cystitis
- 3- bladder neoplasia
- 4- urethral obstruction by calculi or tumor; as a complication of bladder surgery.
- 5- bladder catheterization,

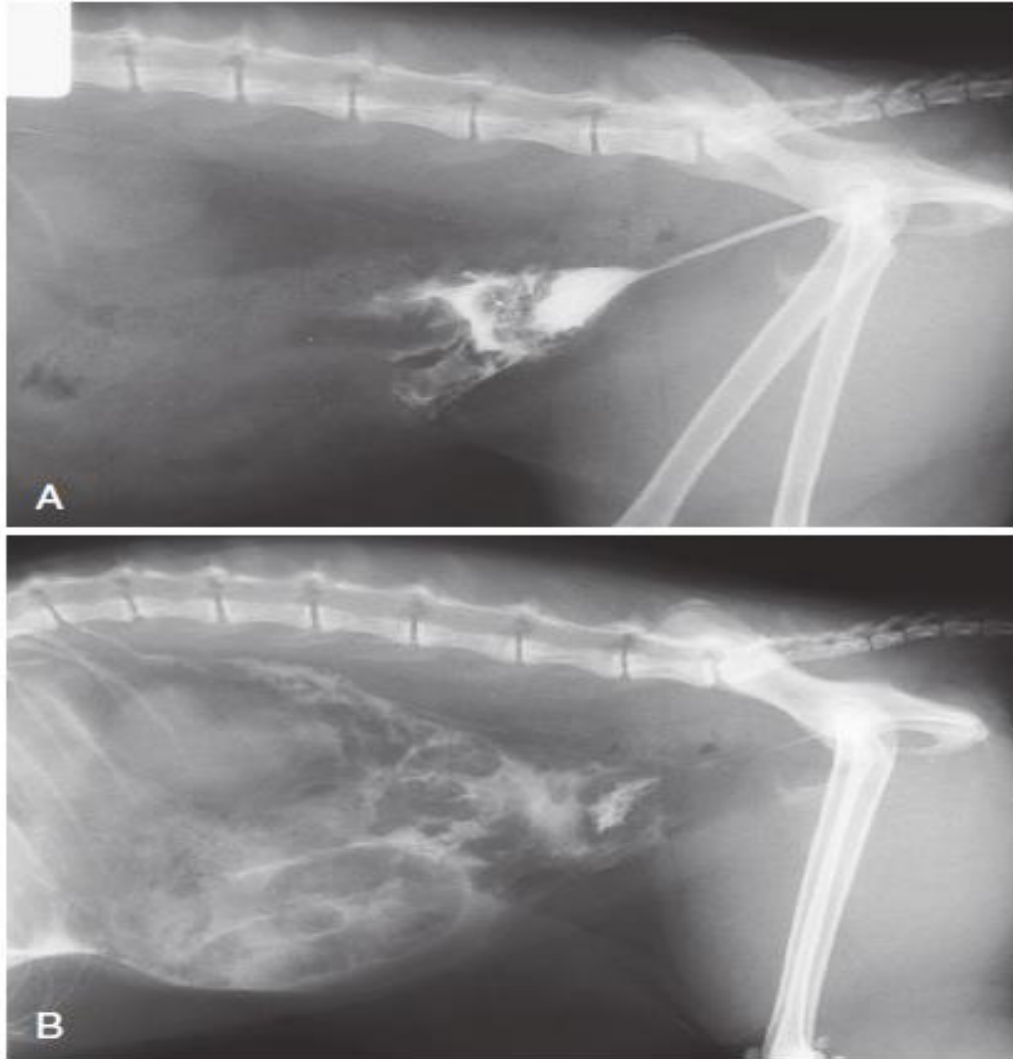


Figure 116-13 Positive-contrast retrograde urethrocytogram demonstrating massive bladder disruption and leakage of contrast into the abdomen, immediately after contrast injection (A) and a few minutes later (B).

Bladder Calculi

Urolithiasis is common in dogs and cats, Urolithiasis often involves one or more sites in the urinary tract, but the bladder is the most common location for occurrence and removal of calculi.

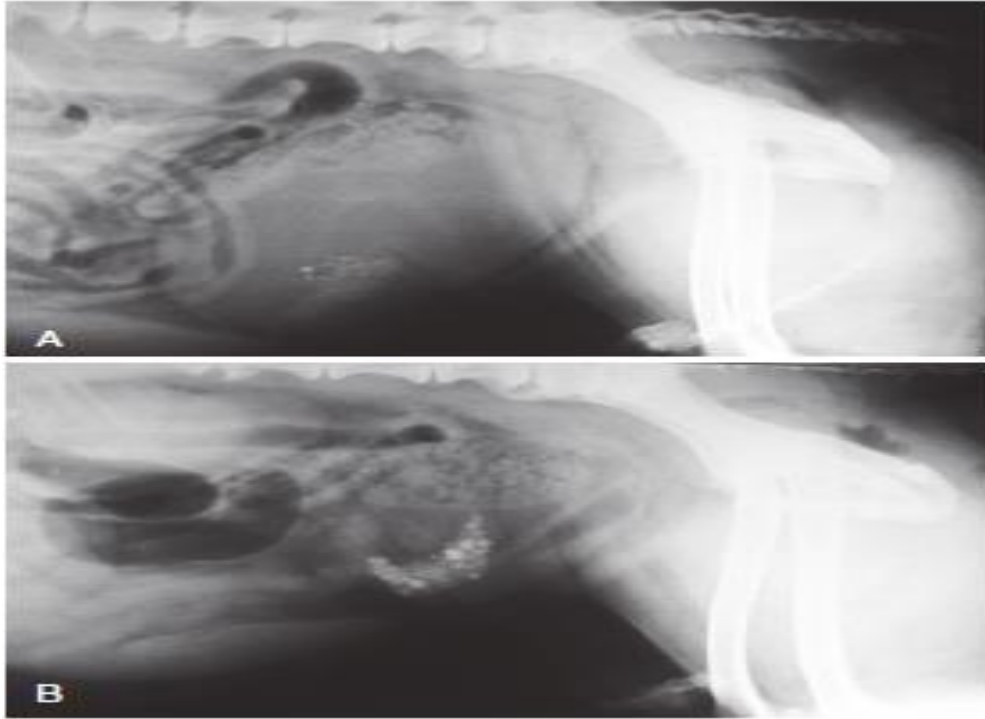


Figure 116-14 Plain radiograph demonstrating a hugely distended bladder containing radiopaque cystic calculi and multiple distal urethral calculi (A). After retrograde urethral flushing of the urethral calculi into the bladder, it no longer appears distended, and more calculi are visible in the bladder lumen (B).

Polypoid Cystitis

Polypoid cystitis is an uncommon, non-neoplastic inflammatory disease that affects the bladder mucosa. Polypoid masses, are located cranioventrally in the bladder.

The cause of polypoid cystitis is unknown but **may be associated with recurrent urinary tract infections, cystic calculi.**

The most common presenting sign is hematuria caused by hemorrhage from the polyp. Ultrasonography, cystoscopy, or contrast radiography will establish the presence of a bladder mass.

Biopsy of the mass, either surgically or via cystoscopy, is required for a definitive diagnosis

Surgical options for resection of the polyps include partial cystectomy,

The surgical resection of the polyps reduces the risk of recurrence compared with medical management alone.

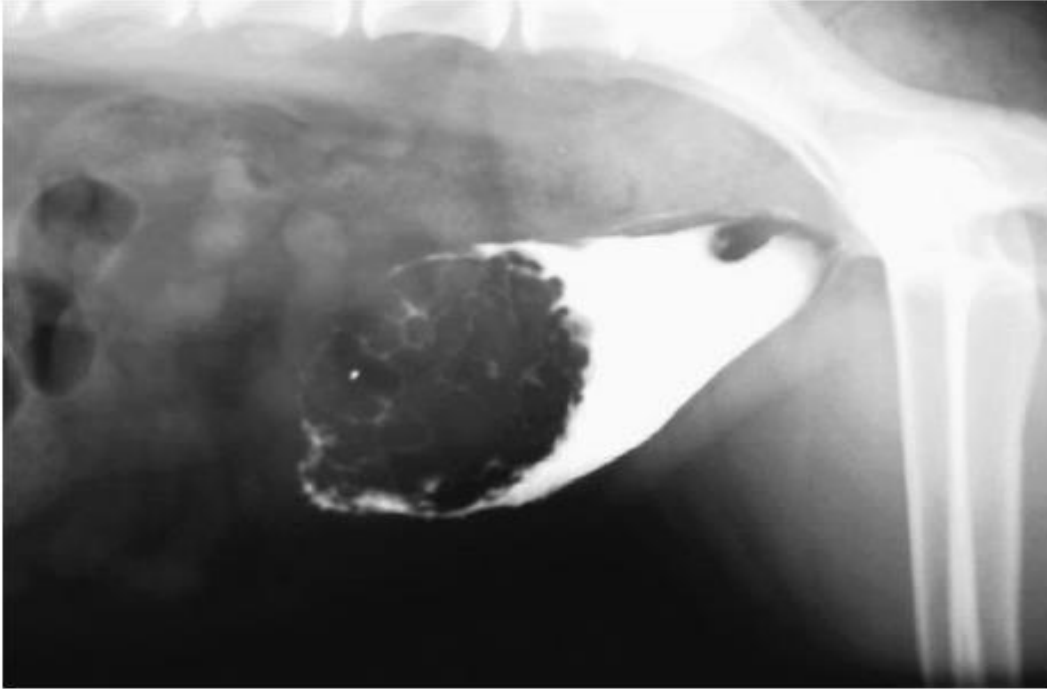


Figure 116-18 Positive-contrast cystogram demonstrating an extensive, multifocal bladder tumor in a dog, which was diagnosed as lymphoma.

Bladder Neoplasia

Bladder neoplasia is rare in dog; Metastatic tumors of the bladder are rare, but local extension into the bladder from tumors.

SURGICAL TECHNIQUES

Cystotomy

Indications for cystotomy include removal of calculi, repair of bladder trauma, biopsy or resection of bladder masses, biopsy and culture of the bladder.

Surgical Techniques

- 1- midline laparotomy incision is made from the umbilicus to the pubis (curving parapreputially through the skin and subcutaneous tissue in male dogs).
- 2- The bladder is identified and isolated from the rest of the abdomen with moistened laparotomy swabs, and a stay suture is placed in the apex.

- 3- stab incision is made into the bladder using a scalpel blade, and residual urine and blood are removed using suction.
- 4- The incision is extended cranially or caudally (or both) as needed, and further stay sutures are placed at the edges of the cystotomy incision.
- 5- The bladder lining is inspected, and any abnormal areas are biopsied.
- 6- The easiest place to excise a full-thickness bladder biopsy is at the edge of the cystotomy incision
- 7- The bladder is closed by simple continuous suture absorbable suture material.
- 8- Routine closure of the linea alba, subcutaneous tissue, and skin is performed.

Cystectomy

Indications for partial cystectomy include excision of a

- 1- patent urachus,
- 2- bladder diverticulum,
- 3- discrete bladder neoplasia or polyp,
- 4- Bladder necrosis.

Surgical Techniques

The neurovascular supply to the bladder enters dorsally in the trigone region

If a large amount of bladder has been excised, a temporary cystostomy tube or an urethral catheter may be placed to maintain bladder decompression in the postoperative period.

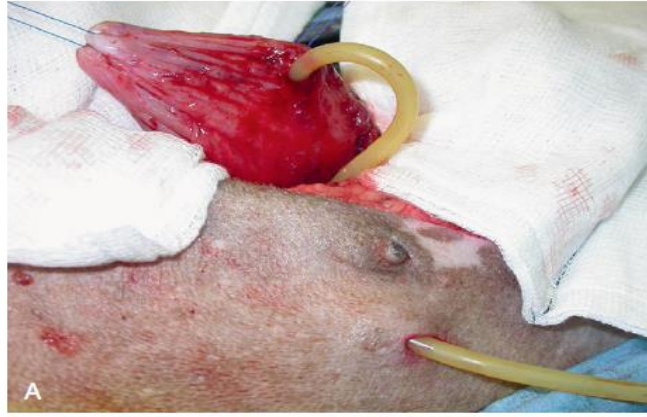
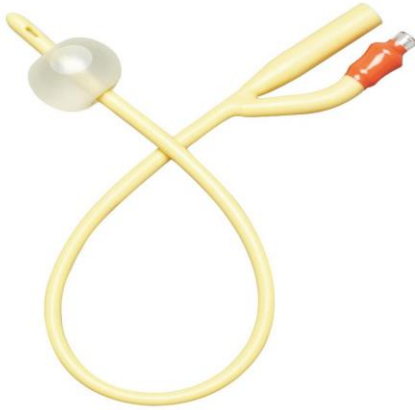- 1- If the cystectomy includes one or both ureteral orifices, then a ureter can be cut and reimplanted into a different location in the bladder wall.
- 2- The same closure of cystotomy wounds (see above) can be applied to cystectomy incisions

Cystostomy

Indications for a temporary cystostomy tube include

- 1-stabilization of an animal with lower urinary tract obstruction,
- 2-Bladder or urethral trauma,
- 3- After bladder or urethral surgery.

Cystostomy tubes are traditionally placed surgically via a ventral midline laparotomy. A Foley or mushroom-tipped catheter (8- to 14-Fr) is placed for short-term use. Foley catheters are retained in the bladder by inflating the bulb with saline but are not recommended for long-term use because the balloon may deflate over time.



A purse-string suture (using absorbable suture material) is placed in the bladder, and a small stab incision is made within it. The distal end of the cystostomy tube is placed into the bladder, and the purse-string suture is tightened around the tube. Three or four nonpenetrating interrupted sutures are placed from the bladder around the tube to the corresponding region on the abdominal wall to pexy the tube in place.

The external tube is secured to the body wall using simple interrupted suture.

The cystostomy tube must remain in place for at least 7 days to allow time for a secure adhesion to form between the bladder and body wall.

Urine may leak from the stoma for a few days after tube removal until the stoma heals.

Cystopexy

Cystopexy is the creation of a surgical attachment between the bladder and abdominal wall.

Animals with perineal hernia may present with displacement of the bladder into the hernia, and cystopexy is recommended to prevent future episodes of bladder retroflexion.

The bladder is sutured to the abdominal wall in three longitudinal rows of six simple interrupted sutures using 2 metric (3-0) polypropylene. Sutures are placed through the seromuscular and submucosal layers of the bladder wall and the transverse abdominal muscle of the abdominal wall.