

METHODS OF PREGNANCY DETECTION

A variety of methods can be used to detect pregnancy; many are common to all species whereas others are species-specific.

There are four broad categories which are:

- 1- Management.
- 2- Clinical.
- 3- Ultrasonography.
- 4- laboratory-based.

PREGNANCY DETECTION IN THE MARE

I. Management methods:

Failure to return to oestrus is a good sign that a mare is pregnant. The demonstration of the signs of oestrus usually requires the presence of a teaser stallion.

II. Clinical methods:

1-Vaginal examination.

Vaginal speculum examination is performed 18 to 21 days after ovulation, usually in conjunction with examination of the reproductive tract per rectum. Speculum examination is not indicated unless per rectum examination is equivocal. The presence of a dry, pale, tightly closed cervix with the external os protruding into the center of the cranial vagina is suggestive of pregnancy.

2-Rectal palpation.

- Palpation of the conceptus is first possible at 17–21 days, when it is a small soft swelling of 2.4–2.8 cm in diameter or is an apparent ‘gap’ in the otherwise tonic horn. It is more easily felt between 21 and 30 days, but still only the cranio ventral portion of the distension can be appreciated.

-At 35 days, it is 4.5–6 cm and at 40 days 6–7 cm in diameter – about the size of a tennis ball. Thereafter, it is not possible for the conceptual swelling to be completely cupped within the palm of the hand.

- By 60 days, it is becoming oval in shape and measures approximately 13 × 9 cm,

- whilst by 90 days it has increased to approximately 23 × 14 cm. There is a natural variation in the size of the conceptual swelling in mares of similar size and ovulation dates owing to the variation in the volumes of fetal fluids present.

- At about 100 days, it is often possible to ballotte the fetus as it floats in the fetal fluid of the uterine body. Growth of the fetus and reduction in tension of the fetal sacs enable the examiner to palpate parts of the fetus in the uterine body from the end of the fourth month onwards.

III. Ultrasonographic methods:

Major advantages of transrectal ultrasound for pregnancy detection in the mare are:

- Earliest positive detection of pregnancy, with the embryonic vesicle visible as early as day 9 or 10 of gestation. The accuracy of vesicle detection approaches 99% by 15 days of gestation.
- Permits fetal sexing at approximately days 60 to 70 of gestation.

IV. Laboratory methods:

1- Milk or blood progesterone.

Plasma progesterone concentrations remain elevated just before, or during, the time when the mare would have returned to oestrus.

Blood or milk samples collected 16–22 days after service should have elevated progestogen concentrations in pregnant mares, whilst in non-pregnant mares the levels would be low and typical of those obtained at oestrus. 100% accuracy in diagnosing pregnancy using this method.

2- Identification of eCG. :

Recall that eCG is produced by endometrial cups in the pregnant mare uterus beginning on days 36 to 40 of gestation. The period of detection of eCG in mare serum is limited to days 40 to 120 of gestation.

To test for presence of eCG, serum either can be submitted to a reference laboratory for testing or can be analyzed with a commercially available “mareside” kit.

3- -Blood oestrogens.

A method of detecting pregnancy by determining the concentration of total oestrogens in the peripheral blood. By 85 days of gestation the concentration should exceed the maximum values obtained in non-pregnant mares.

4- -Urinary oestrogens.

Oestrogens (oestrone and oestradiol-17 β) are present in the urine of pregnant mares in sufficient amounts for accurate detection by a chemical method. between 150 and 300 days of gestation. Very little equipment is required and the results are easy to interpret. It is nearly 100% accurate between 150 and 300 days.

5- **Serum Early pregnancy factor (EPF)** is an immune-suppressive glycoprotein associated with early pregnancy, first identified in the mouse (Morton et al., 1974) and subsequently identified in a number of domestic species, including the horse. Using the **rosette inhibition test** it has been possible to detect the presence of EPF in the serum from peripheral blood from as early as 7–10 days after ovulation.

Methods of pregnancy diagnosis in cattle

1- Management methods

Failure return to estrus and persistence of the corpus luteum.

Failure of regression of the CL at about 21 days, as determined by trans-rectal palpation, provides a method of anticipating that the cow is probably pregnant. Rectal examination at about this time in an individual which was close to, or at, estrus would demonstrate the presence of a turgid, coiled uterus and a mucoid vaginal discharge.

How reliable is failure to return to estrus as a method of diagnosing pregnancy? This will be dependent on the efficiency and accuracy of estrus detection.

2- Laboratory methods

-Identification of early pregnancy factor/ early conception factor.

Early pregnancy factor (EPF) is an immunosuppressive glycoprotein associated with pregnancy. Commercially available test kits are available which use the 'dip-stick' principle and can detect early conception factor (ECF) in serum and milk from as early as 3 days after artificial insemination, although more accurate results are obtained if samples are taken later at 7 to 8 days

-Assay of pregnancy-specific protein B.

This protein has been identified in the maternal serum of cows from 24 days of gestation; the concentration is measured by radio-immuno-assay .

It is secreted by the Binucleate cells of the trophoblastic ectoderm, and thus its presence can be used to confirm pregnancy.

However, since it has a long biological half-life it can also be identified in serum for many weeks postpartum; for the same reason, false positives can occur after embryonic or fetal death.

At present, it can only be measured by radioimmunoassay (RIA) but, with the development of suitable enzyme-linked immune-sorbent assay (ELISA) methods, it could well become an 'on farm' diagnostic test .

Using RIA to detect the protein, a 90% accuracy at 30 days of gestation. It has been shown that there is a good correlation between pregnancy-specific protein B (PSPB) in peripheral plasma concentrations and fetal numbers, and thus the method can be used to identify twins .

-Progesterone concentration in plasma and milk.

Since the CL persists as a result of the pregnancy, if a blood sample is taken at about 21 days after the previous oestrus, progesterone levels remain elevated.

If the cow is not pregnant and is close to or at oestrus then the progesterone levels will be low. Although this is a perfectly valid and reliable laboratory method,

-Oestronesulphate in milk.

Estronesulphate is quantitatively one of the major estrogens in the milk of pregnant, lactating cows. During gestation the concentration increases gradually so that after day 105 it is present in the milk of all pregnant animals, whereas in non-pregnant individuals it is low or undetectable; the source of the hormone is the feto-placental unit. The identification of oestronesulphate in the milk of a cow at 105 days of gestation, or later, is a very reliable method of pregnancy diagnosis.

3-Clinical methods

-Transrectal palpation

Palpation of the amniotic vesicle. This method involves the palpation of the amnion towards the end of the first month of pregnancy.

Palpation of the allantochorion (membrane slip).

This method is dependent upon the facts that in the cow, attachment of the allantochorion to the endometrium occurs only between the cotyledons and the caruncles, and that the intercotyledonary part of the fetal membrane is free.

The method was first described by Abelein (1928) (see Cowie, 1948), who reported that it could be used from the fifth week of gestation.

Unilateral cornual enlargement. Unless there are twin conceptuses, one in each horn, it is possible to detect a difference in the size of the two horns.

Palpation of the early fetus. At about 45–50 days of gestation the amniotic sac becomes less turgid, and it is sometimes possible to palpate directly the small developing fetus. This should be done with care.

Palpation of caruncles /cotyledons. Caruncles / cotyledons first become recognisable by rectal palpation at 10–11 weeks as roughened elevations

Palpation of the cervix. Evidence of pregnancy can be assumed when there is tension on the cervix. In the non-pregnant or early pregnant cow or heifer the cervix is freely movable from side to side. However, as pregnancy advances the cervix becomes less mobile and it is pulled forwards and downwards over the pelvic brim.

Hypertrophy of the middle uterine artery and development of fremitus .

In a non-gravid or early pregnant cow, identification of the middle uterine artery by palpation is usually not possible transrectally.

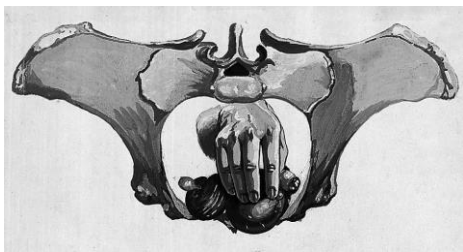
At some stage during pregnancy it will cease to have the usual pulse, and instead it will become a 'thrill' or tremor, which is called fremitus.

There is considerable variation in the time at which the change can first be felt and also when it becomes continuous. The earliest the author has been able to detect it is at 86 days.

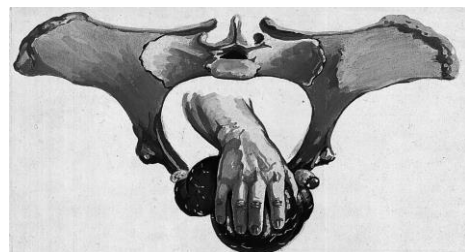Palpation of the late fetus.

Palpation of the fetus, either per rectum or by abdominal ballotement, is diagnostic of pregnancy. The ease of palpation depends upon the size of the cow, the degree of stretching of the suspension of the uterus, and the degree of relaxation of the rectum and uterine wall.

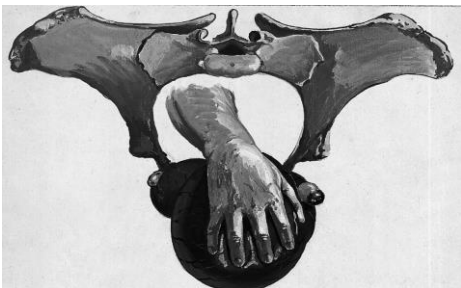<https://youtu.be/w-j8HL2OHEY>



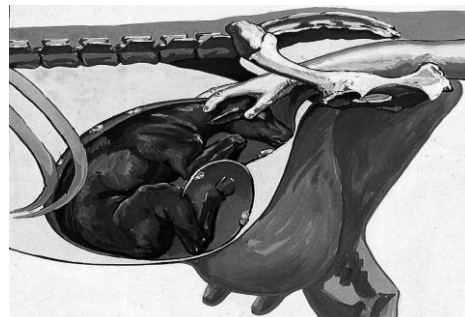
Uterus gravid 70 days.



Uterus gravid 90 days.



Uterus gravid 110 days.



Pregnancy approaching term.

Accuracy of pregnancy diagnosis by rectal palpation.

The most likely reason for making a false positive diagnosis is subsequent embryonic or fetal death, which is impossible to exclude. Other reasons for false positives are incomplete uterine involution, pyometra, mucometra and hydrometra, and failure to retract the uterus.

The inexperienced person may well make a diagnosis of pregnancy because the uterus is out of reach and cannot be palpated. It is important that the diagnosis should be made on the identification of positive signs. It is perfectly permissible to admit uncertainty, to note in writing the changes that can be identified, and to re-examine the animal in 2 or 3 weeks' time.

-Vaginal examination.

Examination may be manual or visual. In the latter case, an illuminated speculum is used. The condition of the vaginal mucous membrane does not afford definite clinical evidence of pregnancy, for the degree of 'dryness' and blanching which occur during the diestrous period are very similar to those of pregnancy. It is to the external os of the cervix that attention is directed. During pregnancy the secretion of the cervical glands becomes gelatinous and tough, forming a plug for sealing the canal. In many cases the seal covers or protrudes from the external os. It has developed by day 60.

4-Ultrasonographic methods

Using the ultrasonic fetal pulse detector, which employs the Doppler principle, it is possible to identify the fetal heart from 6–7 weeks using a rectal probe.

Realtime B-mode grey-scale ultrasound scanning is the method of choice for the early diagnosis of pregnancy in the cow.

5- Other methods**-Mammary glands.**

Mammary changes during pregnancy are best observed in primigravida.

The teats of the pregnant heifer begin to enlarge about the fourth month, and with a little experience it is an easy matter to distinguish them from those of the non-pregnant or early pregnant animal.

From the sixth month the mammary glands become more firm to the touch and their enlargement can be seen. Hypertrophy is progressive and is particularly marked during the terminal month.

The abdominal wall, particularly in the region of the umbilicus, may also become swollen by oedema.

-Abdominal ballottement.

This is often possible as early as 7 months of gestation in some small breeds such as the Jersey. However, in some fat cows of large breeds it is sometimes impossible even at term. The method involves fairly vigorous pummeling of the ventral abdomen and flank with clenched fists. The object is to push the fetus, which is floating in the fetal fluids, away from the body wall and then identify it as it swings back against the fist which is kept pressed against the abdominal wall.

Methods of pregnancy diagnosis in the ewe

There are a large number of published methods of diagnosing pregnancy in the ewe, many of which are historical, and these have been reviewed in detail.

1- Management methods

Traditionally the method used by shepherds is the observation that ewes, which have been marked by a 'keeled' or 'raddled' ram, fail to be marked again within 16–19 days.

Beyond 100 days of gestation the fetus may be palpated through the abdominal wall, and development of the udder is then obvious in primipara. The best way to ballot the fetus is to have the ewe standing normally and to lift the abdomen repeatedly immediately in front of the udder; the fetus can be felt to drop on to the palpating hand.

2- Ultrasonographic methods

The fetal pulse detector (Doppler) has been used to diagnose pregnancy in ewes, and two types of probe are available. The external probe is applied to the skin surface of the abdomen just cranial to the udder. The fleece in this region is sparse and with transmission gel applied to the end of the probe it is slowly moved over the surface.

The ewe can be restrained either standing or sitting on her haunches. Characteristic sounds indicate the presence of the fetal heart ('tack, tack, tack') or vessels ('swish, swish, swish'); the frequency greatly exceeds that of the mother's heart rate, except in late gestation when the fetal heart rate is reduced.

More recently the use of the linear-array real-time ultrasonography for the diagnosis of pregnancy in sheep .

The use of transabdominal ultrasonography for pregnancy diagnosis is often preferred in sheep in the field. The pregnancy can be determined by transabdominal ultrasonography 30 days after breeding. Its application is recommended between day 40 and 80 after breeding because of its high accuracy rate.

Moreover pregnancy can be determined transrectally by means of ultrasonography.

The authors showed the successful pregnancy diagnosis using 5 MHz transducer after day 25 of gestation. The earliest indication of pregnancy, based on scanning extraembryonic fluid and membranes, has been observed on day 15 after breeding .

3- Laboratory methods

- Vaginal biopsy.

the stratified squamous epithelium of the vaginal mucosa is sensitive to the hormonal changes that occur during the oestrous cycle and pregnancy

- Milk and plasma progesterone.

Pregnancy can be diagnosed on the fact that in the pregnant ewe the CLs persist and hence peripheral progesterone concentrations will remain elevated at 15–18 days after mating. In

lactating ewes it is also possible to determine the progesterone levels in milk. Plasma and milk progesterone values in pregnant sheep 18–22 days after mating were similar (3.7 ng/ml), whereas in non-pregnant ewes they were 1 ng/ml.

- **Rosette inhibition titre (RIT) test.**

This is an established test for determining the immunosuppressive potential of anti lymphocyte serum which has been applied to determining the presence of an ‘early pregnancy factor’ (EPF) in ewes. In ewes which were subsequently found to be pregnant, the factor could be demonstrated as early as 24 hours after mating.

The RIT test is time-consuming and difficult to maintain, the development of a radio-immunoassay or ELISA for EPF should provide a more reliable method.

4- Clinical methods

Radiography.

Both dorsoventral and lateral radiographs can be taken. Using an exposure time of 0.3–0.5 seconds and depending on the dorsoventral dimension of the ewe, fetuses were detectable from 70 days of gestation.

The overall accuracy of the method in detecting pregnancy increases with advancing gestation: 52% between 66 and 95 days to 100% after 96 days.

Palpation of caudal uterine artery.

Identification of enlargement of the caudal uterine artery has been reported as a fairly reliable method of diagnosing pregnancy; the technique requires patience and skill. The arteries can be palpated per vaginam as they run outside the anterior vaginal wall at the 10 o’clock and 2 o’clock positions .

Peritoneoscopy.

91% accuracy of pregnancy detection between 17 and 28 days by means of direct inspection of the uterus and ovaries with a laparoscope, using general anaesthesia.