

## 4-Marek's Disease (M.D)

\* **Definition:** it is the most **common lymphoproliferative** disease of chickens which is characterized by **mononuclear infiltration** in **peripheral nerves**, Gonad, iris, **various viscera**, muscle and skin.

\* **Etiology:**

M.D virus is a **cell-associated Herpes** virus.

\*There are **3** serotype diseases isolates:-

1-serotype **1** include **Mild and Very** virulent MD.

2-Serotype **2** includes **pathogenic** (non-oncogenic) isolate (**Intermediate**).

3-Serotype **3**, the Turkey Herpes virus (**HVT**).

\* **Transmission:-**

1-**Direct or indirect** contact between chickens by **airborne** route.

2-**Epithelial cells** in the keratinizing layer of the **feather follicle** replicate fully infectious virus and these cells serve as a **source** of contamination to the environment and to other chickens.

3-Contamination **poultry house dust** remains infectious for at least several months at 20-25 °c and for years at 4°c.

4-Many apparently normal birds are **carrier** that can transmit the infection.

5-Insects (Darkling beetles).

\* **Incubation Period:-**

It is **difficult** to determine the incubation period, under field conditions, MD outbreaks sometimes occur in **unvaccinated** layer chickens as young as **3-4 weeks**. Most of the serious cases begin after **8-9 weeks**.

\* **Clinical Signs:**

**Depend on its form:-**

1- Neuronal or Classical Form.

2-Visceral or Acute Form.

3-Occular Form (gray eye).

4-Skin Form.

5-Transient Paralysis (Neck paralysis).

**1-Classical (Neuronal) form:**

1-Depend on **Peripheral N.** affected, and those associated with **asymmetric** progressive **paresis** and later complete **spastic paralysis** of one or more of the extremities.

2-Involved **Brachial N., IschiticN.** is common leading to progressive spastic paralysis of leg and wing respectively, **characteristic** clinical presentation is a bird with one leg stretched forward and the other back as result of unilateral paresis or paralysis of leg, while when wing involve, there is drop of the wing.

3-Involved **Cervical N.**, there may be **torticulus**, and **flaccid paralysis** of the neck.

4-If **Vagus N.** involved can result in paralysis and dilation of the crop and gasping.

5-If nerves of intestinal tract affected there is **impaction and diarrhea** and loss of weight.

**2-Visceral M.D (Acute form):**

1-Characterized by **proliferate diffuse lymphomatosis**, involvement and enlargement of liver, following the **liver, gonad**, spleen, kidney, lung, proventriculus and heart.

2- The enlargement of affected organs due to **accumulated lymphocytes**.

3-Initially characterized by high proportion of birds with severe **depression**.

4-Many birds become **dehydration, emaciated and comatose**, other may **die** without extensive clinical disease.

**3-Occular Form (Gray eye):**

1-**Blindness** may result from involvement of iris.

2-Affected eye gradually lose their ability to **accommodate** to light intensity.

3-The **pupil** at first become **irregular** and at advance stages is only a small **pinpoint** opening.

**4-Skin Form:**

Skin tumor localized around the **feather follicles** that result **ruffled** feather because no supply blood to feather.

### **5- Transient Paralysis (Neck paralysis):**

1-Affected birds display varying degrees of ataxia and (**partial or whole body paralysis**) lasting **1-2 days**.

2-Many affected birds recover to few weeks later from clinical M.D.

3-The disease is result from **vasogenic brain edema**.

4-**Nonspecific signs** such as **weight loss, paleness, anorexia and diarrhea** maybe observed especially in bird in which the course is prolong.

5-Under commercial condition, **death** often results from **starvation** and **dehydration** because of **inability to reach food and water**.

#### **\*Morbidity and Mortality rate:-**

In general, mortality is nearly equal to morbidity.

\*Prior to use of vaccines, mortality from **25-30%** and as high as **60%**, but when use of vaccines **5%** in most countries.

#### **\*Gross lesion:-**

##### **1-Nerve lesions:**

1-Changes **not** seen in the brain but lesions can be found in one or more **peripheral nerves**.

2-Severly affected peripheral nerves may show **loss of cross-striations, gray or yellow discoloration**, and sometimes **edematous** appearance.

3-**Localized or diffuse enlargement** cause the affected portion to be **2-3 times** normal size, in some cases much more.

4-Because lesions are often **unilateral**, it is helpful to compare opposite nerves.

##### **2-Visceral organs:**

1-**Lymphomas** may occur in one or more of variety of organs.

2-**Lymphomatous** lesions can be found in the gonad (especially the **ovary**), lung, heart, mesentery, kidney, **liver, spleen, bursa**, thymus, adrenal gland, pancreas, **proventriculus**, intestine, iris, **skeletal muscle and skin**.

**3-Visceral lymphomas** are common in more **virulent** virus of the disease.

**4-MD lymphomas** in most viscera appear as diffuse **enlargements**, sometime to several times the normal size, and diffuse **white or grayish discoloration**.

**5-Diffuse infiltration of liver**, gives the surface of **coarse granular appearance**.

**6-Mature ovaries**, marked involvement is indicated by a **cauliflower-like appearance**.

### **\*Histopathology lesion:-**

**1** In **Peripheral nerves**, **2 main types of lesions:-**

**1- (Type A), Neoplastic in character**, consisting of masses of proliferative lymphoplastic cells, in some cases **demyelination and Schwann cell proliferation**.

**2-(Type B), Inflammatory**, and is characterized by **diffuse**, light to moderate infiltration by **small lymphocyte** and plasma cells, usually with edema and sometimes **demyelination and Schwann cell proliferation**.

**2** **Visceral organs, lymphomatous** lesions in visceral organs are more uniformly proliferation in nature than those in nerves, cellular composition consisting of diffusely proliferating **small to medium lymphocytes, lymphoblast**, reticulum cells, and plasma cells rarely present.

### **\*Immunity:-**

1-M.D can be **immunosuppressive** effects.

2-Immunological response.

3-Vaccinal immunity.

4-Immunological resistance.

### **\*Diagnosis:-**

1-Viral isolation.

2-Serological ELISA.

3-lesion and histopathology.

**\*Vaccination:-**

1-**Commercially** available vaccines have been derived from all **three serotypes** for use either alone or in combination.

2-All vaccines are used most commonly as **single dose** in **day old** chicks, usually administered at the hatchery.

3-A significant level of protection is developed within about a **week** and protection **lasts throughout the life** of the chicken although the vaccines **do not** prevent superinfection with pathogenic field viruses.

**\*Serotypes vaccine:**

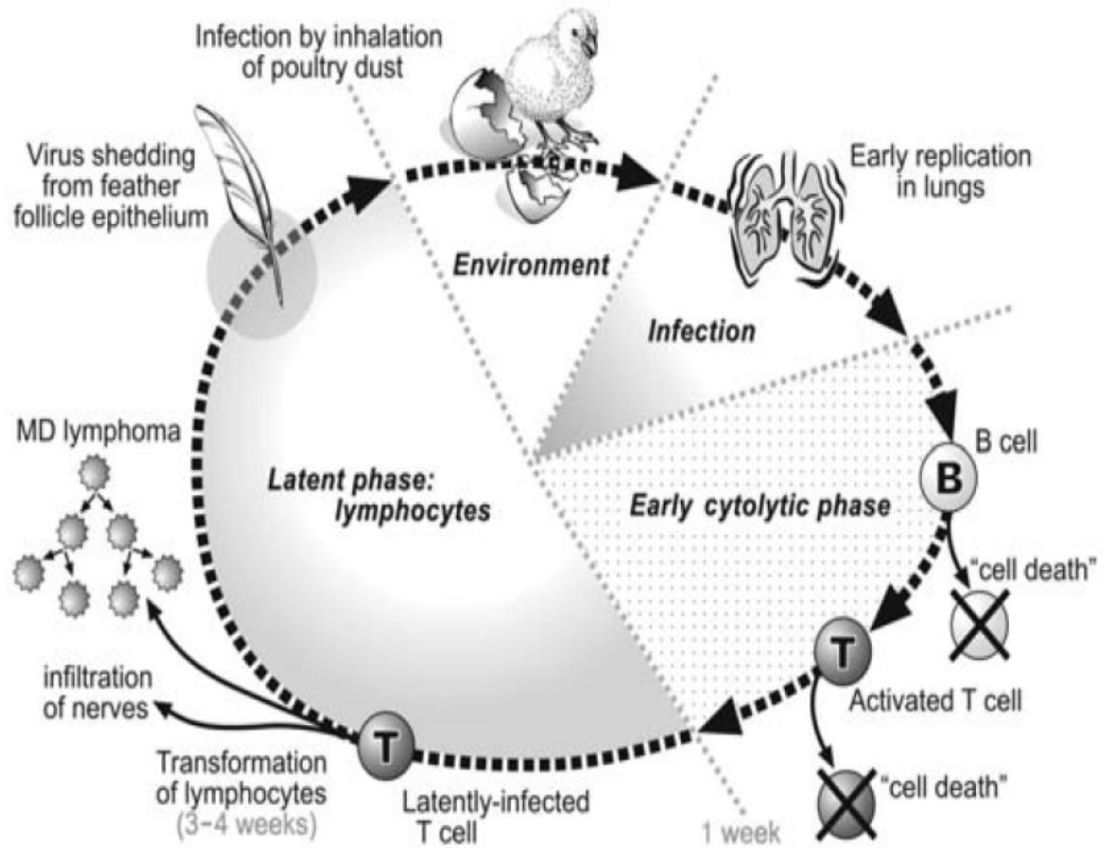
\*Attenuated Mildly virulent Serotype 1 —————→ **CVI 998** (Rispen), it is a cell associated vaccine.

\*Serotype 2 vaccines —————→ **SB-1**, a cell associated vaccine.

\*Serotype 3 vaccines:

**HVT** —→ **FC-126- cell associated vaccine.**

**HVT** —→ **FC-126- cellfree.**



15.19. Schematic diagram showing the different stages of MD pathogenesis including the virus shedding from the feather follicle epithelium and the transformation of T lymphocytes in susceptible birds.