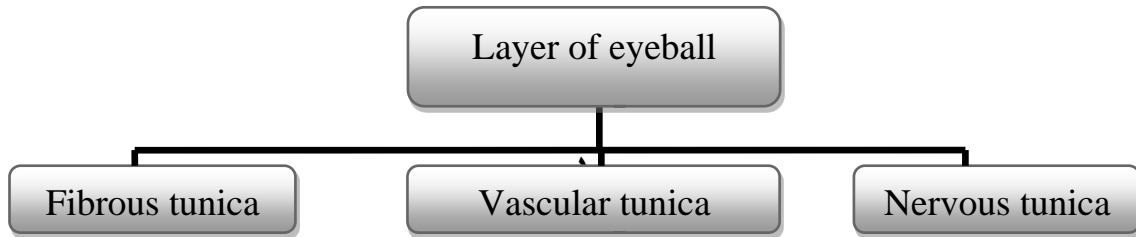


# The eye



## 1-Fibrous tunica :

- a. Cornea.
- b. Sclera.

## 2-Vascular layer :

- a. Choroid.
- b. Ciliary body
  - Ciliary muscle
  - Ciliary processes
- c. Iris .

- Tapetum lucidum

## 3- Nervous layer :

- a- Retina
  - Zona iridica
  - Zona ciliaridica
  - Zona optica

- Optic disc
- Chambers:
  - 1- Anterior chamber
  - 2- Posterior chamber
  - 3- Vitreous chamber
- **Aqueous humor**
- **Vitreous humor**


- **Accessory structure:**

- १-Upper & lower eye lid
- २- Lateral & medial commissures or canthi
- ३-Eye lashes
- ४-Lacrimal gland
- ०-Conjunctiva
- १-Third eye lid (nictitating membrane)

- **Muscle of the eye :**

- १-Levator palpebral superior properious muscle
- २-Dorsal rectus muscle
- ३-Ventral rectus muscle
- ४-Medial rectus muscle
- ०-Lateral rectus muscle
- १-Dorsal oblique musle
- २-Ventral oblique muscle
- २-Retractor bulbi muscle

- **Nerve supply :**

- १- Oculomotor  Dorsal branch (१,२)  
Ventral branch (३,४,२)
- २-Trochlear (१)
- ३-Abducent (०,२)

