

Affection of Salivary Gland

Dr.Hiba A.Sh.

5th Stage

Anatomy of Salivary gland:-

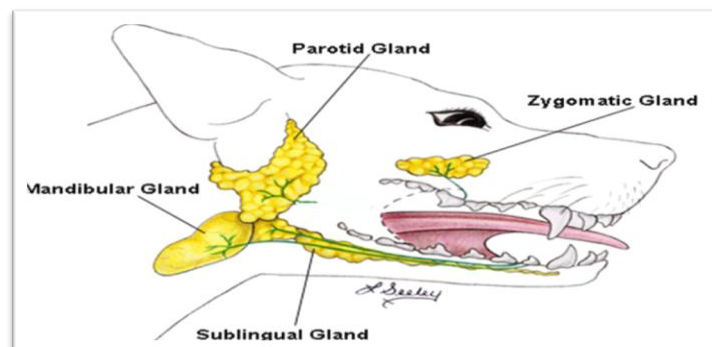
The major salivary glands are located some distance from the oral cavity & empty their secretion via long ducts. They includes:-

- 1-Parotid salivary gland.
 - 2-Mandibular salivary gland.
 - 3-Sublingual salivary gland.
 - 4-Zygomatic or Buccal salivary gland.
- Smaller one are present at soft palate, lips & tongue.

In Dogs:-

There are 4 main pairs of salivary glands:-

The Parotid, Mandibular, Sublingual, & the Zygomatic glands, which are the dorsal buccal glands in other animals.

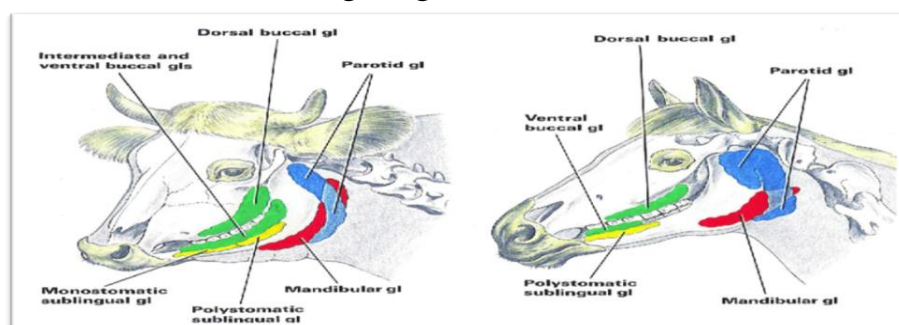


Salivary glands in dog

In horses & ruminants:-

There are 3 main pairs of salivary glands:-

The Parotid, Mandibular, & Sublingual glands.



Salivary glands in horse & cattle

1-Parotid salivary gland:-

*It is pale, yellow & V-shaped or pyramid in shape.

*In large animals; It is the largest salivary gland & situated chiefly in space between the wing of atlas & ramus of mandible.

*The parotid duct (Stenson's duct) leave gland either as a single or union of (2-3) radicules that unite soon after they leave the gland & open into the mouth in the area of the upper 3rd maxillary tooth in large animals & in upper premolar tooth in small animals.

2-Mandibular salivary gland:-

*In large animals its small, long, narrow, located beneath the parotid salivary gland & extended between atlas & hyoid bone.

*In small animals the mandibular salivary gland located ventral to the parotid salivary gland & lie in front of the maxillary vein & linguofacial vein.

*The mandibular duct open at the base of lingual frenulum.

3-Sublingual salivary gland:-

*In large animals, the gland situated beneath the mucous membrane of mouth between body of tongue & ramus contact with mandibular salivary gland.

*The duct open on small papillae on the sublingual from (caruncle) either with that of mandibular salivary gland or about (1cm) caudal to it.

Advantages of saliva:-

- 1-Keep the mouth moist.
- 2-Wet & lubricate food materials.
- 3-Dissolved some elements of food.
- 4-Enables of appreciation of taste.
- 5-It initiates digestion of starchy food.

Affection of salivary glands:-

Salivary glands affection can be divided into 2 types:-

A-Congenital:-

Are associated with agenesis or atresia of the parotid ducts, resulting in a fluid-filled swelling proximal to the obstruction site.

B-Aquired:-

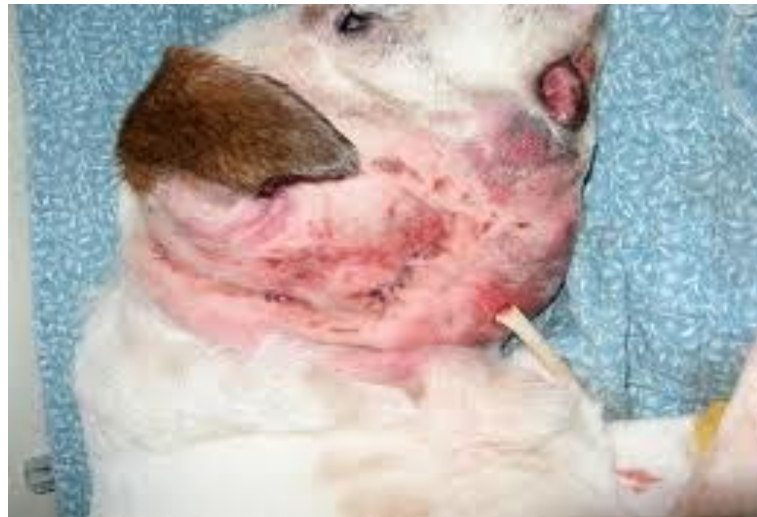1-Trauma:-

Fresh wound of the gland must be sutured after thorough cleaning and debridement, the leaking wound has a great tendency toward spontaneous closure.

A permanent fistula may result after wounding of salivary duct by accident or after operation.

The fistulous tract has usually a form of a fibrous tube and should not be curetted, it should be excised by circular incision around the fibrous wall and cut it close to the salivary duct, introduce a polyethylene catheter into the duct, secure the end in the mouth with few sutures and in the neck and cut off the excess.

Close the wound where the fistula has been excised in several layer with cat gut, the skin wound is closed with interrupted silk suture. The tube facilitates normal drainage of saliva.



Trauma leading to rupture of salivary gland

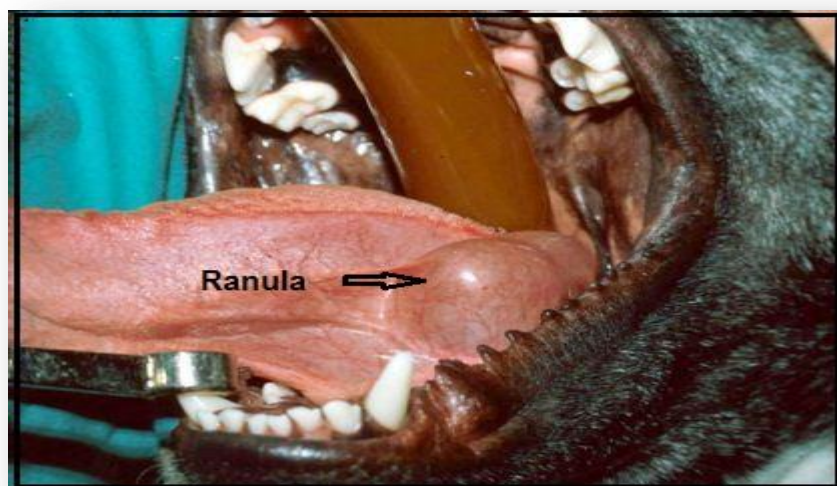
2-Salivary Mucocele (Sialoceles or Salivary Cyst):-

A salivary mucocele is a collection of saliva that has leaked from a damaged salivary gland or salivary duct, and has accumulated in the tissues. This is often noted as a fluctuant, painless swelling of the neck or within the oral cavity. While often inaccurately called a salivary cyst, mucoceles are lined by inflammatory tissue (called granulation tissue) which is secondary to the inflammation caused by the free saliva in the tissues, while a cyst is lined by epithelial (glandular) tissue which is itself responsible for the production of the fluid. Salivary mucocele may be classified as follows:-

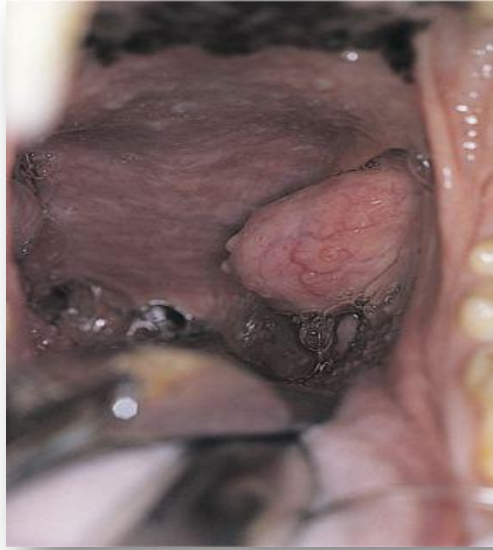1-Cervical Mucoceles:- This is probably the most common type of mucocele. It is a collection of saliva in the upper neck region, at the angle of the jaw, or between the mandibles.



2-Sublingual Mucoceles (also called a Ranula):- Another frequent location for the formation of a mucocele is on the floor of the mouth alongside the tongue. This is frequently seen in association with a cervical mucocele.



3-Pharyngeal mucocoeles:- This type of mucocele is much less common. It is essentially a variation of the cervical mucocele, but the fluid accumulation is almost entirely within the throat (pharynx).



4-Zygomatic Mucocele:- This is a very rare type of mucocele where the saliva is originating from the small zygomatic salivary glands which are located just below the eye. Or is a collection of saliva ventral to the globe.

5-Complex Mucocele:- It's consisting of two or more types, occur in some animals.

Etiology of Salivary Mucocele:-

- 1-Trauma.
- 2-Foreign bodies.
- 3-Sialoliths.

The sublingual salivary gland is the most commonly involved.

Signs of Salivary Mucocele:-

- 1-Saliva commonly accumulation in the cranial cervical or inter-mandibular area, sublingual, or pharyngeal tissues.
- 2-Saliva irritates the tissue & cause inflammation.
- 3-During this initial phase the swelling may be firm & painful, but the animals is asymptomatic.
- 4-Granulation tissue forms in response to the inflammation & prevents saliva from migrating further.

Diagnosis of Salivary Mucocele:-

- 1-From clinical sings & pathological finding.
- 2-Radiographs (Sialograph) may determine which gland is involved.
- 3-Histopathologic examination.

Treatment of Salivary Mucocele:-

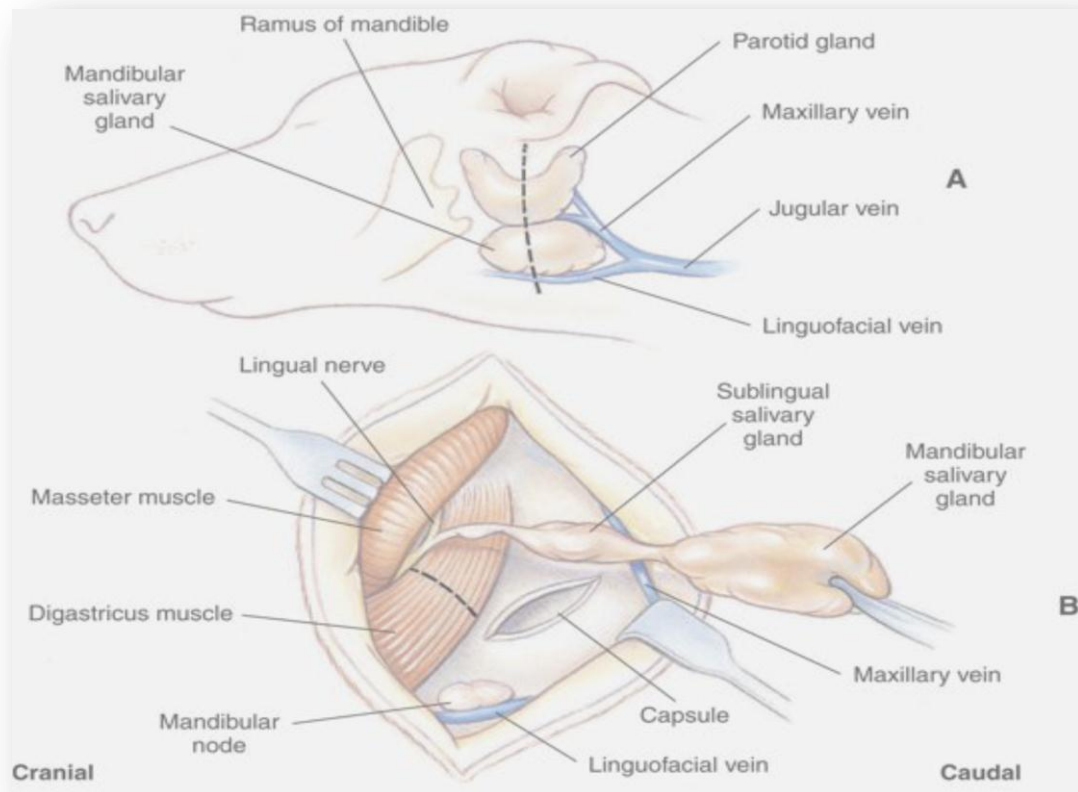
A-Medical treatment:-

Repeated drainage or injection of cauterizing or anti-inflammatory agents does not eliminate mucocele; however, it complicates subsequent surgery by leading to abscessation or fibrosis.

B-Surgical treatment:-

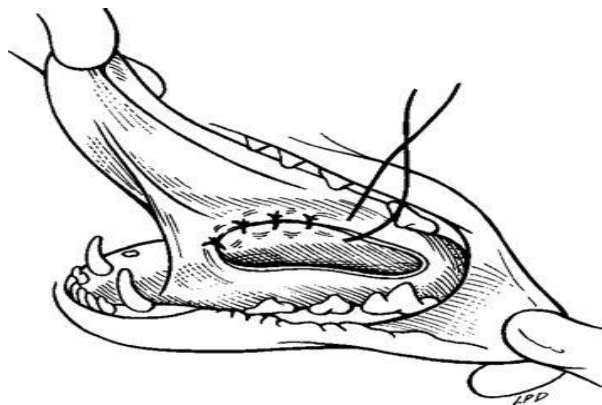
Complete excision of the involved gland-duct complex & drainage of the mucocele are curative.

- 1-General anesthesia recommended.
- 2-Animal in lateral recumbency & maximum opening of the mouth.
- 3-The mandibular & sublingual salivary glands are excised together because the sublingual gland is intimately associated with the mandibular salivary gland duct; removal of one would traumatize the other.
- 4-Locate the mandibular salivary gland between the linguofacial & maxillary veins as they join the external jugular vein.
- 5-Incise the skin, subcutaneous tissue, & digastrics muscle from the angle of the mandible caudally to the external jugular vein to expose the fibrous capsule of the mandibular gland.
- 6-Incise the capsule & dissect it away from the mandibular & mono-stomatic sublingual salivary glands.
- 7-Ligation the artery (branch of the great auricular artery) & veins as they are encountered on the dorso-medial aspect of the gland.
- 8-Dissection continued cranially, to follow the mandibular & sublingual ducts, towards the mouth.
- 9-Incise the fascia between the masseter & digastrics muscles, to completely expose the entire mandibular & sublingual salivary gland.
- 10-Ligation & transect the mandibular –sublingual gland-duct complex just caudal to the lingual nerve.
- 11-Lavage the surgical site, & appose the digastrics muscle, with horizontal mattress.
- 12-Close the dead space with a few sutures in the capsule & deep tissue. Routinely appose superficial muscles, subcutaneous tissue, & skin.



Marsupialization:-

Is the process of incising a mucocele & suturing the edges of the salivary duct with the mucosa of oral cavity. The interior of the mucocele suppurates & gradually closes by granulation.



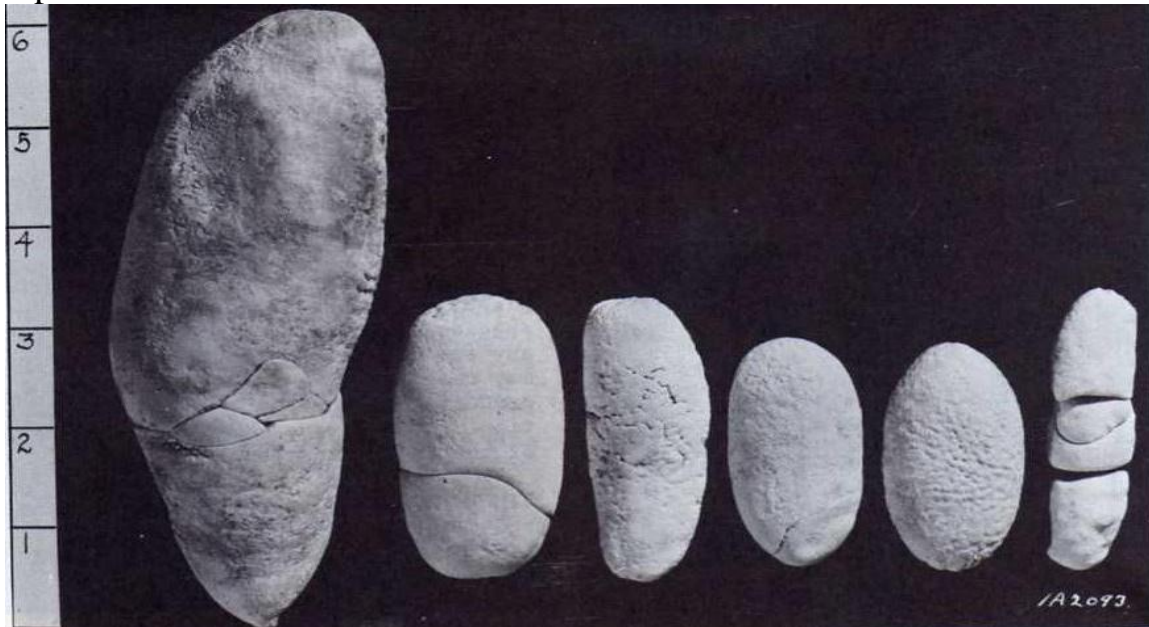Note:-

- The dog is more frequently affected by salivary mucoceles than cat.
- Salivary mucoceles are not cysts. Cysts is a cavity lined by epithelium, whereas the granulation tissue lining of a mucocele which produced secondary to inflammation caused by free saliva.

3-Sialoliths: -

Presence of calculi (stones) within salivary duct these calculi vary in size & consist mainly of calcium carbonate (CaCO_3).

Usually occurred due to presence of small foreign body or tissue debris within the salivary duct as a result of salivary inflammation. These act as a nidus for deposition of calcium salt around it to form the stone.



Signs of sialoliths:-

Swelling of regional gland.

Surgical treatment:-

- 1-The operation can be done under local analgesia & tranquilization, but a general anesthesia is usually preferable.
- 2-Make an incision over the stone swelling along the course of the duct, through the skin, tissue & duct, taking care to avoid accompanying veins & arteries.
- 3-Expose the calculi & remove it.
- 4-Suture the salivary gland duct with catgut using continuous suture pattern.
- 5-Suture the skin with silk using interrupted suture pattern.

Affection of tongue

Dr.Hiba A. Sh.

5th stage

The Tongue:-

Is a muscular organ filling the oral cavity having many papillae on its dorsal surface which have a mechanical or gustatory function or both.

Function of Tongue:-

- 1-In large ruminants act as prehensile organ for gathering of grass & ingestion of food.
- 2-Carry gustatory receptors for taste sensation.
- 3-Help in formation of food bolus ready for swallowing.
- 4-Groom of fur especially in cat.
- 5-Thermoregulation especially in dog by panting.
- 6-Vocalisation help in sound production through its complicated movements.

Note:-

In dog there is lyssa which is a cartilage embedded in ventral surface of apex while in horse embedded in median plane of dorsal surface.

Anatomy of the Tongue:-

****Muscles of the Tongue:-***

- 1-Intrinsic muscles:- forming the bulk of the tongue responsible for changing of tongue shape during swallowing & chewing.
- 2-Extrinsic muscles:-connect tongue to skeleton (hyoid bones) responsible for its gross movements.

****Blood supply of the Tongue:-***

By lingual artery & sublingual artery.

(Common carotid A.-----external carotid A.-----lingo-facial trunk-----lingual & sublingual arteries).

****Innervations of the tongue:-***

- 1-Taste-----two third of tongue (apex, body) by facial cranial nerve. While the last third of tongue by glossopharyngeal with vagus cranial nerves.
- 2-Other sensation (pain, heat....etc) by mandibular nerve is a branch of fifth cranial nerve.
- 3-Motor by hypoglossal cranial nerve.

Affection of Tongue:-

The affection of tongue can be divided into 3 parts:-

A-Congenital :-

1-Ankyloglossia or microglossia:-

Refers to incomplete or abnormal development of the tongue. It is often referred to as “***bird tongue***” in dogs and may be a component of the fading puppy syndrome. Affected puppies have difficulty nursing and do poorly. Oral examination reveals missing or underdeveloped lateral and rostral thin portions of the tongue that result in prehensile and motility disturbances. It is generally lethal.



2-Macroglossia, or large tongue:-

Is seen in belted Galloway cattle but resolves with age and is rarely clinically significant. Degrees of Macroglossia could result in excessive drooling, tongue injury, or excessively dry tongue.



3-Epitheliogenesis imperfecta, or “smooth tongue,”:-

Is a condition of incomplete development of the lingual filiform papillae that is transmitted as an autosomal recessive trait in Holstein, Friesian, and Brown Swiss cattle. It results in excessive salivation and an unthrifty condition.

B-Acquired affection of Tongue:-

1-Trauma:- trauma of the tongue occurs in all species of animals, and all the affected animals will show the following signs:-

- 1-Inability to protrude the tongue for feeding.
- 2-Salivation.
- 3-Halitosis.

Treatment

Cleaning of the area after insertion of mouth gag and application of local antiseptics and antibiotics.

2-Lacerations:- can occur after street accident or by sharp tooth fragment, if laceration are deep, suture under general anesthesia & a tension suture (vertical mattress) and non- absorbable suture material are used. In case of severe laceration partial glossectomy was done.

Amputation in cattle must be avoided because of the loss of prehensile function of the tongue.

Severe tongue lacerations sometimes require a partial glossectomy. Because of the tongue's crucial role in prehension of food, as much of the tongue as possible should be preserved.

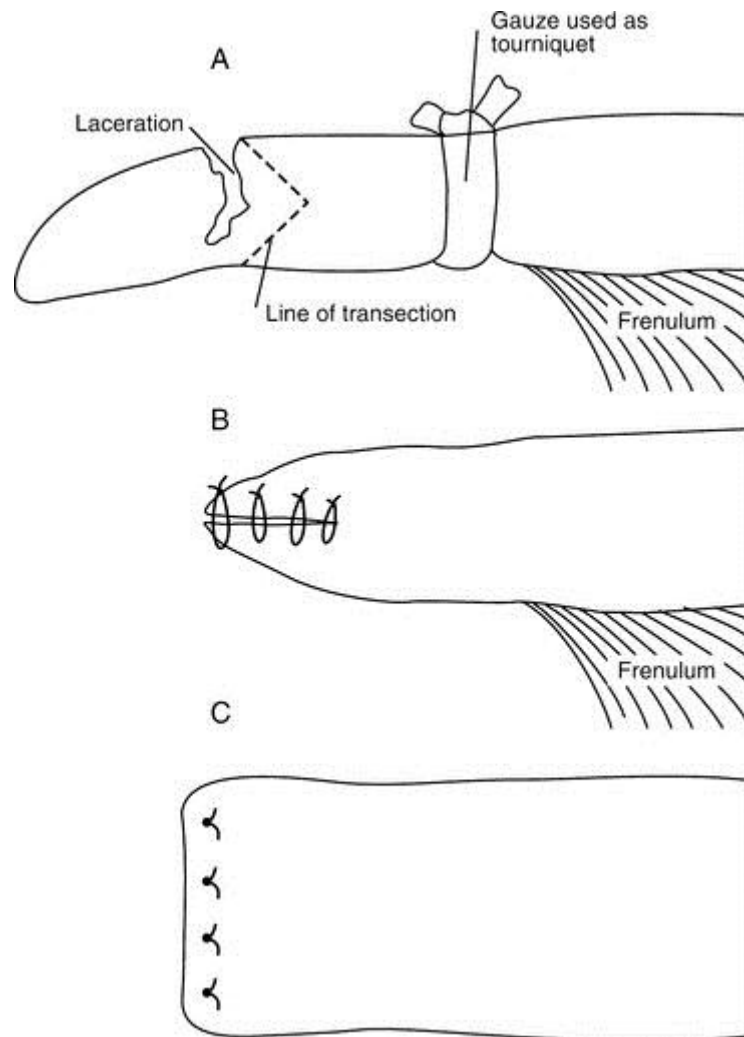
-In preparation for surgery The animal is anesthetized and placed in lateral recumbency.

- A tourniquet (made of rolled gauze) is applied proximal to the intended transection site.

-The tongue is transected so that the dorsal and ventral aspects protrude beyond the center.

-The ventral and dorsal aspects are sutured together with an interrupted horizontal mattress pattern with a no.-1 or no.-2 absorbable sutures.

- The animal should receive systemic antibiotics postoperatively and should be fed a soft diet (not pasture) for best results.



3-Paralysis of the tongue (glossoplagia):-Paralysis of the hypoglossal nerve and the tongue shown one side of the mouth. In bilateral paralysis the whole tongue is flaccid and hangs out of the mouth.

Causes:-

- 1-infection or neoplasm along the course of the nerve.
- 2-Lead poisoning and botulism.

Treatment:-

- 1-tonics.
- 2-Water and nutrients must be administered by stomach tube.

4-Snake bite:-The tongue can be bitten by a snake as it protruded to bring grass or hay into the mouth.

Clinical sings:-

- 1-gangrene and septicemia.
- 2-Swelling of the inter mandibular region.
- 3-Swelling of the tongue and discolored and protruded stiffly from the mouth.

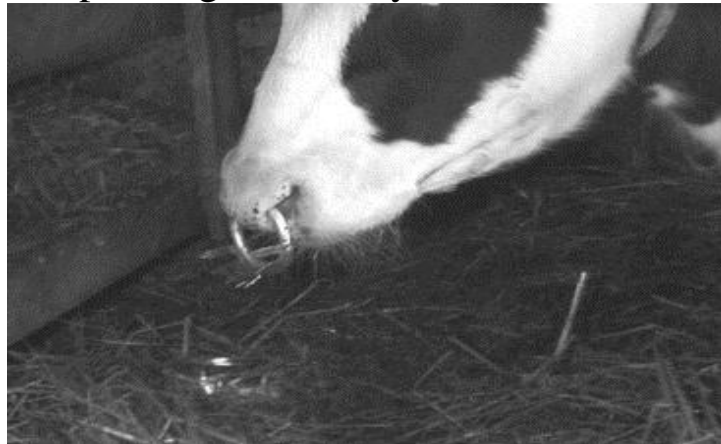Treatment:-

- 1-immediate local I.M. injection of antivenin and antibiotics (penicillin and streptomycin) is essential.
- 2-Giving water and feed.
- 3-Incise the tongue to drain away exudates.

C-Bad habits affections:-

1-Self suckling:-

Self-suckling is most commonly treated by using a nasal ring with a burr or nasal flap and individual housing. If these more conservative treatments are not successful, a partial glossectomy can be considered.



Treatment:-

1-Non-surgical treatment:-

By using of metallic rings or tags at the frenulum for about (6month) . the non-surgical methods induce pain during protrusion of tongue.

2-Surgical treatment:-

Partial glossectomy.

Two surgical techniques have been created to perform a partial glossectomy to prevent self-suckling in animals. The techniques are performed with sedation and local infiltration of lidocaine or general anesthesia. Both techniques alter the tongue's contour to prevent the animal from forming a U-shaped tongue for suckling. For the ventral glossectomy technique, an elliptical incision is made that is approximately 5 cm at its widest part and starts rostral to the frenulum attachment on the tongue and extends rostrally 2.5 cm caudal to the tip of the tongue. Each side of the ellipse is incised at an angle toward the midline to facilitate

closing the defect, as shown in. The lateral glossectomy technique removes half of the tip of the tongue. Again, the incision is extended at an angle to facilitate closing the tongue similar to what is shown in, except in a different plane.

